

---

# REPLANTATION OF THE UPPER EXTREMITY: INDICATIONS AND OUTCOMES

---

**BY KEVIN C. CHUNG, MD, MS, AND AMY K. ALDERMAN, MD, MPH**

*Since the introduction of microsurgical technique over 40 years ago, replantation of the upper extremity has been performed throughout the world with regularity. Instead of focusing solely on survival of the replanted parts, hand surgeons are more aware of the functional, health-related quality of life and economic issues associated with this complex procedure. Derived from several decades of experience, the indications for replantations in the upper extremity have become more defined and the functional outcomes have improved. In indicated cases, replantation procedures provide patients with reconstruction that is unmatched by any other means. This article discusses the current status of replantation and condenses the particulars of performing upper-extremity replantations.*

*Copyright © 2002 by the American Society for Surgery of the Hand*

**T**he history of replantation is rich, with a heritage founded in both the Western and Eastern worlds. The initial efforts of American and Chinese surgeons have led to impressive developments of microsurgical technology and skill. This progress has introduced a new conceptualization of managing upper-extremity trauma, in which function is the benchmark for success. The boundaries are now

pushed beyond the mere approximation of vessels. As Dr. Littler stated, “The result of vessel anastomosis is dramatic and signals survival—but it is only the beginning, for other less urgently required structures must be restored functionally if the initial success is to extend beyond the mere retention of a parasitic member.”<sup>1</sup>

The initial attempts of digit replantation date back to the early 19th century, which was characterized by autografting techniques. In 1814, Dr. William Balfour successfully autografted a house carpenter’s index finger after initially attempting his new procedure on his own son’s amputated digits.<sup>2</sup> Over 100 years later, surgeons were still attempting the same procedure with the addition of a tube flap, which was first suggested by Dr. Sir Harold Gillies in 1940. He suggested removal of the skin envelope of the severed

---

*From the Section of Plastic Surgery, Department of Surgery, The University of Michigan Medical Center, Ann Arbor, MI. Address reprint requests to Kevin C. Chung, MD, MS, Section of Plastic Surgery, The University of Michigan Medical Center, 1500 E Medical Center Dr, 2130 Taubman Center, Ann Arbor, MI 48109-0340. E-mail:kecchung@umich.edu*

*Copyright © 2002 by the American Society for Surgery of the Hand  
1531-0914/02/0202-0006\$35.00/0  
doi:10.1053/jssb.2002.33319*

digit, which has the greatest vascular requirements, reattaching the bones, tendons, and nerves, which have lower vascular demands, and creating a tube flap for soft-tissue coverage.<sup>3</sup> Dr. Stuart Gordon was intrigued with Sir Gillies' new approach and, in 1944, he performed the first successful autograft of a thumb by using a tube flap from the abdomen.<sup>4</sup> For the next 20 years in replantation surgery, autografting predominated, and many insensate nonfunctional digits were created. Little discussion existed regarding the need for microsurgical techniques for vascular anastomoses or nerve coaptations.

The 1960s symbolized change in many segments of society, including microvascular surgery. As early as 1958, surgeons at Louisville were on the verge of replantation surgery when they repaired 4 upper-limb devascularization injuries by using vein grafts and nerve coaptations.<sup>5</sup> However, the birth of replantation surgery was in 1962 and 1963, on opposite ends of the world, in both the West and East. During this time, the Peoples Republic of China was restructuring her political system after the Communist revolution, isolating China from the free world. In 1973, when the *Chinese Medical Journal* resumed its publication after a 5-year lapse, the Western world discovered the advances that the Chinese were making in replantation surgery. The Chinese surgeons' efforts paralleled the American effort, which was led by Dr. Ronald Malt in Boston.<sup>6</sup> After Richard Nixon facilitated communication between China and the United States, an American replantation team, consisting of leaders in microsurgery such as Drs. Buncke, Kleinert, and Malt, visited China in 1973.<sup>7</sup> During this visit, Dr. Malt, the first to perform an arm replantation on May 23, 1962, met Dr. Chen Chung-Wei, the second to perform replantation in 1963.<sup>7</sup> By this time, Dr. Chen had created the largest replantation center in the world at the Sixth Peoples' Hospital in Shanghai, which by 1973 had performed over 200 replantations of the upper extremity.<sup>6</sup>

These founding fathers displayed considerable insight, identifying factors critical to successful microvascular surgery. For example, Dr. Chen recognized the importance of adequate venous outflow, used vein grafts to obtain tension-free arterial anastomoses, used nerve grafts when nerve gaps could not be repaired primarily, and described secondary tendon transfers for functional improvements.<sup>8,9</sup> Dr. Chen also recognized the hard work of the factory workers who cre-

ated his delicate microsurgical instruments—an effort crucial to his success.<sup>10</sup> For Dr. Malt, his arm replantation, known as the famous *Boston-arm*, gave him a greater understanding of the importance of proper transportation of amputated extremities, bone stabilization, and tension-free anastomoses.<sup>11</sup>

After Drs. Malt and Chen took the initial steps in the world of microsurgery, many talented surgeons eagerly followed. In 1965, Dr. Bunke described experimental amputation and replantation on Rhesus monkey's digital vessels, which were 1 mm in size, by using a Zeiss 2-headed microscope (Zeiss, Jena, Germany).<sup>12</sup> That same year, Dr. Kleinert performed the first successful digital vessel anastomosis in a devascularized thumb,<sup>13</sup> and Drs. Komatsu and Tamai performed the first successful replantation of a completely amputated thumb by anastomosing digital arteries and dorsal veins.<sup>14</sup> By 1968, indications for microsurgery were expanded as John Cobbett performed the first big toe transfer to an amputated thumb.<sup>15</sup> Accompanying these advancements was a greater understanding of the physiology and anatomy crucial for successful microsurgery. For example, in 1964, American journals were encouraging surgeons to expand the indications for dextran beyond volume expansion to include the prevention of early vascular thromboses.<sup>16</sup> Meanwhile, the Chinese were advancing the understanding of microvascular anatomy by recognizing the potential damage to the amputated vessels' intima, which can exist even with normal-appearing adventitia.<sup>17</sup> This observation was later confirmed in the late 1980s by the Australians.<sup>18</sup>

The 1970s were characterized by rapid progress in microsurgery on an international front. The Americans were led by Dr. Harry Bunke, Jr, in San Francisco, who many refer to as the Father of Microsurgery.<sup>19</sup> The Chinese replantation team was centered at the Sixth Peoples' Hospital,<sup>20,21</sup> and the Australians were reporting impressive replantation success rates from their team in Melbourne led by Dr. O'Brien.<sup>6</sup> All of these efforts were enabled through important advances in the 3 Ms of technology: microscopes, microinstruments, and microsuture. And most importantly, microsurgeons were sharing ideas and experiences on an international level, bridging the intellectual gap among physicians that was initially created through political tension between governments.

## EPIDEMIOLOGY

Hand injury rates will vary between and within countries, depending on the current industrial safety standards accompanying agricultural and industrial communities. In the United States, the demographic composition of finger amputation patients and the mechanism of injury has held relatively constant over the past 3 decades. The majority of injuries occur in men, with the ratio of men to women ranging from 5:1 to 6:1,<sup>22,23</sup> and with the average age slightly less than 30 years.<sup>22,23</sup> In 1996, the location of most amputation accidents was an industrial site, accounting for 43% of cases, and the home took second place with 25% of injuries.<sup>24</sup> Machinery, in particular power saws, has been the dominant mechanism of injury,<sup>22,24-26</sup> and the index finger appears to be one of the most common sites of amputation.<sup>22,23,26</sup> In a review of the University of Louisville's experience, the proximal phalanx was the most frequent site of injury (21%), and above-elbow injuries accounted for only 3% of cases.<sup>14</sup> A review of thumb injuries from 1976 to 1985 at the Mayo Clinic found similar results except that men outnumbered women 38:1 and the mean patient age was 36 years.<sup>27</sup> Duke University has also served as a large referral center for digit replantations, averaging 100 cases per year.<sup>28</sup> In their experience, the dominant extremity was injured in 41% of cases.<sup>28</sup> The majority of the injuries (78%) occurred between 6:00 AM and 6:00 PM, however, most of the replantations were performed at night.<sup>28</sup> No significant difference in the incidence of digit amputations was found between the months of the year or between the seasons.<sup>28</sup>

On a national level, the incidence of upper-extremity amputations is unclear; however, the incidence of replantations is modest—1,153 cases in 1996.<sup>24</sup> Through the use of a national database, we found digital replantation surgery to be an uncommon procedure in most U.S. hospitals, involving only 15% of U.S. hospitals in 1996.<sup>24</sup> Sixty percent of these hospitals performed only 1 digit replantation for the year, whereas only 2% performed 10 or more cases.<sup>24</sup> This epidemiologic study highlights the need for designated replantation centers, which would expedite patient transfers to experienced facilities. The predictions of microsurgery's founding fathers regarding centralized replantation centers have not come to fru-

### TABLE 1

#### Indications for Replantation

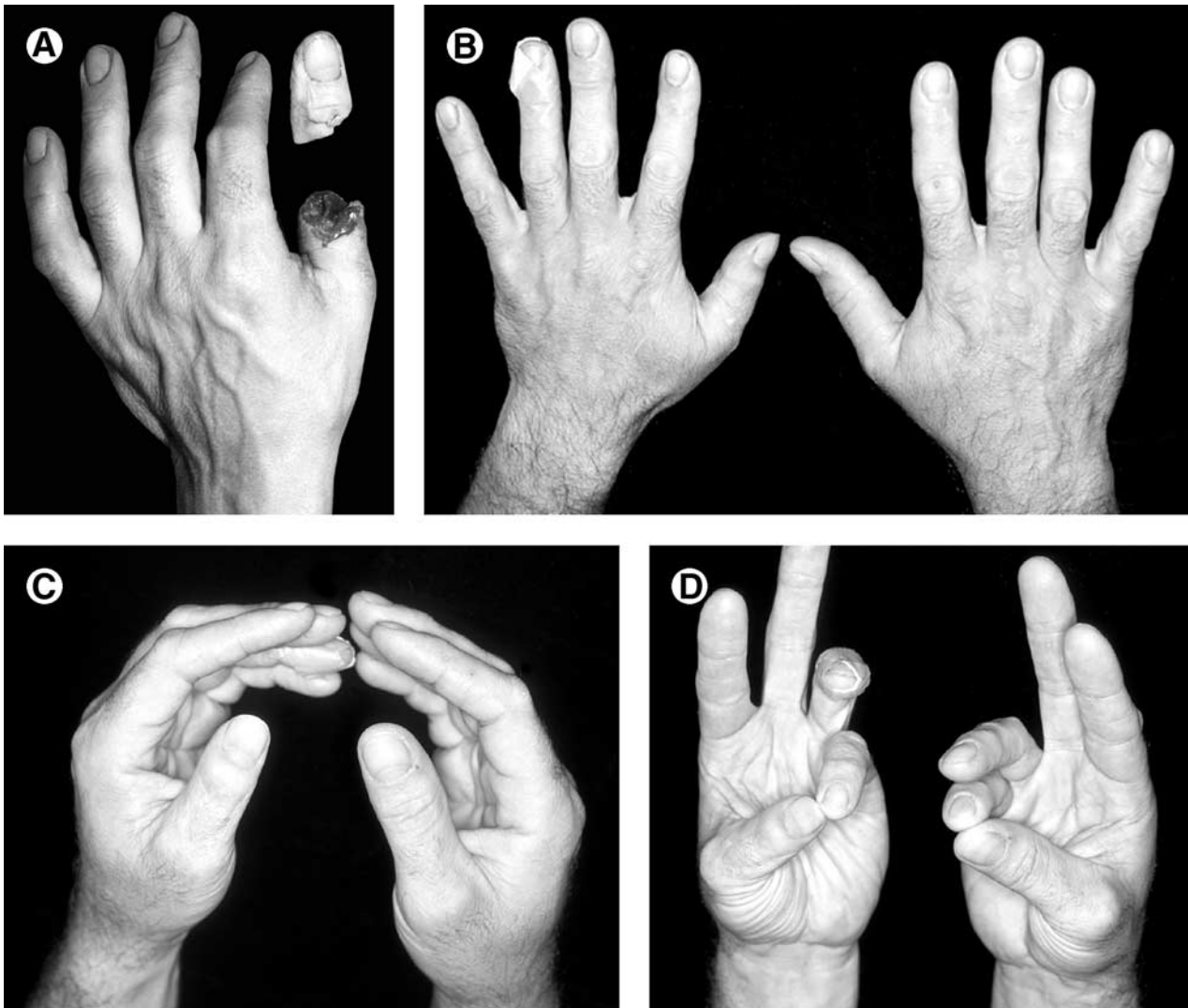
Strong indications
Thumb amputations
Multiple finger amputations
Any amputation in a child
Amputation at the level of the palm, wrist, or forearm
Relative indications
Single digit amputation distal to the FDS insertion
Ring finger avulsion injury

ition. Digit replantation in the United States is still highly fragmented and unorganized.

## INDICATIONS

The indications for upper-extremity replantation are far from timeless, evolving with patients needs, surgeons' skill, and technology (Table 1). However, common to all cases is the critical need to identify the goal of reconstruction, which should be individually targeted to the patient's occupation, hobbies, health, and socioeconomic status.<sup>8,29,30</sup> For the pioneers of microsurgery, tissue success with functional failure was acceptable. Today, function must predominate as the goal, requiring restoration of skeletal stability, joint mobility, power, and sensibility.<sup>29</sup>

Although indications are relative to each patient, most would agree that the absolute indications for replantation are thumb amputations, multiple finger amputations, and any upper-extremity amputation in a child.<sup>8,28,31</sup> In cases of thumb amputations, which can result in a 40% to 50% loss of hand function, secondary reconstructions are technically complex. Although excellent outcomes after toe-to-thumb reconstructions have been reported,<sup>32</sup> many reconstructions are poor substitutes for successfully replanted thumbs.<sup>33</sup> The majority of thumb amputations leave the carpometacarpal joint intact, thereby preserving the positioning mechanism for pinch and grasp. Therefore, replantations distal to the carpometacarpal joint have excellent functional outcomes that do not rely on the mobility of the interphalangeal or metacarpophalangeal joints<sup>31</sup> (Figs 1 and 2). Patients with multiple finger amputations should be considered for replantation of all possible digits. Successful replantation of even a couple of fingers can provide pinch function, which obviates the need for complex secondary recon-

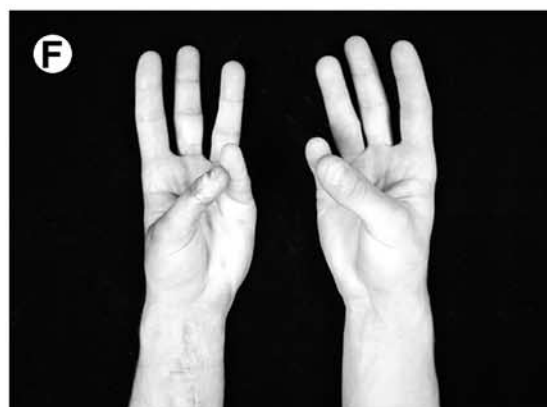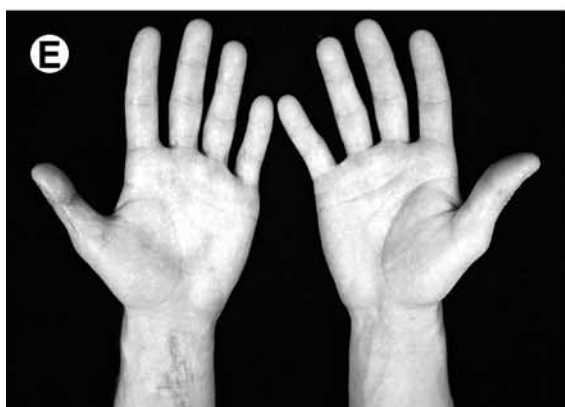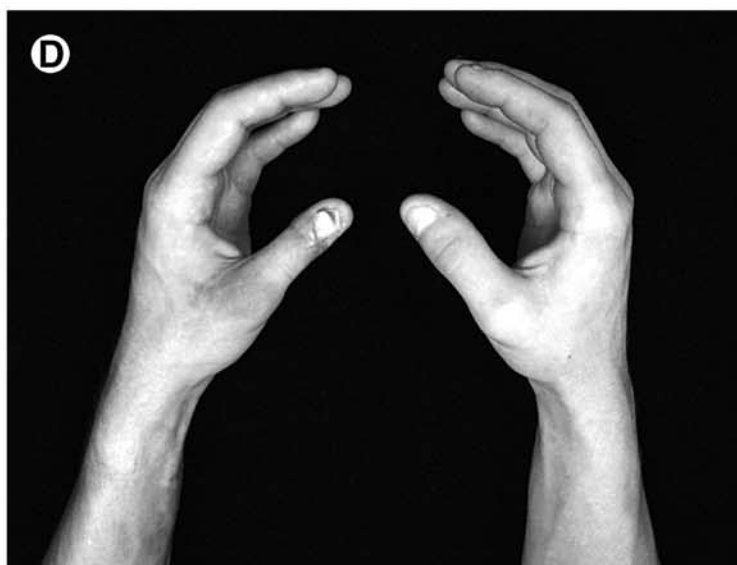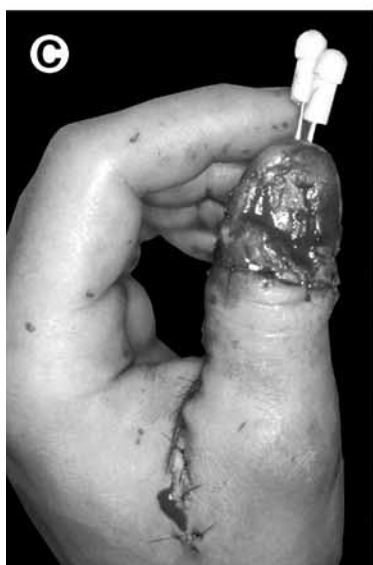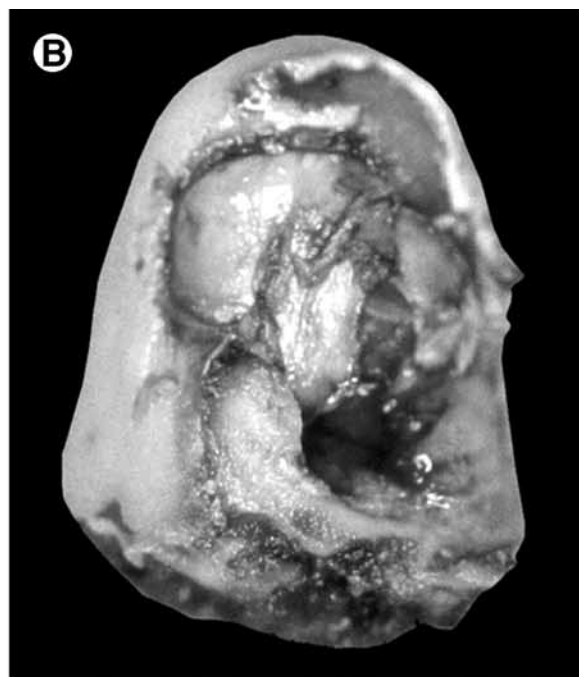


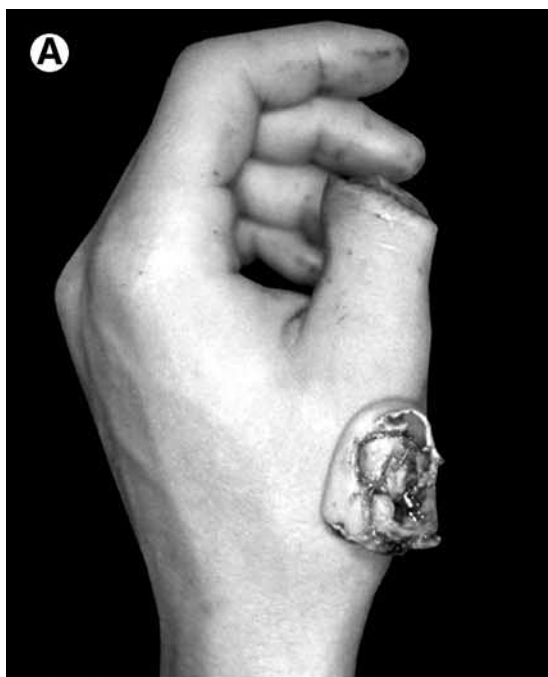**FIGURE 1.** (A) Amputation of the left thumb through the proximal phalanx from a saw injury. The amputated part was in good condition. (B-D) Two-year follow-up of the left replanted thumb. The appearance and function was comparable with the other hand. Two-point discrimination of the replanted thumb was 5 mm.

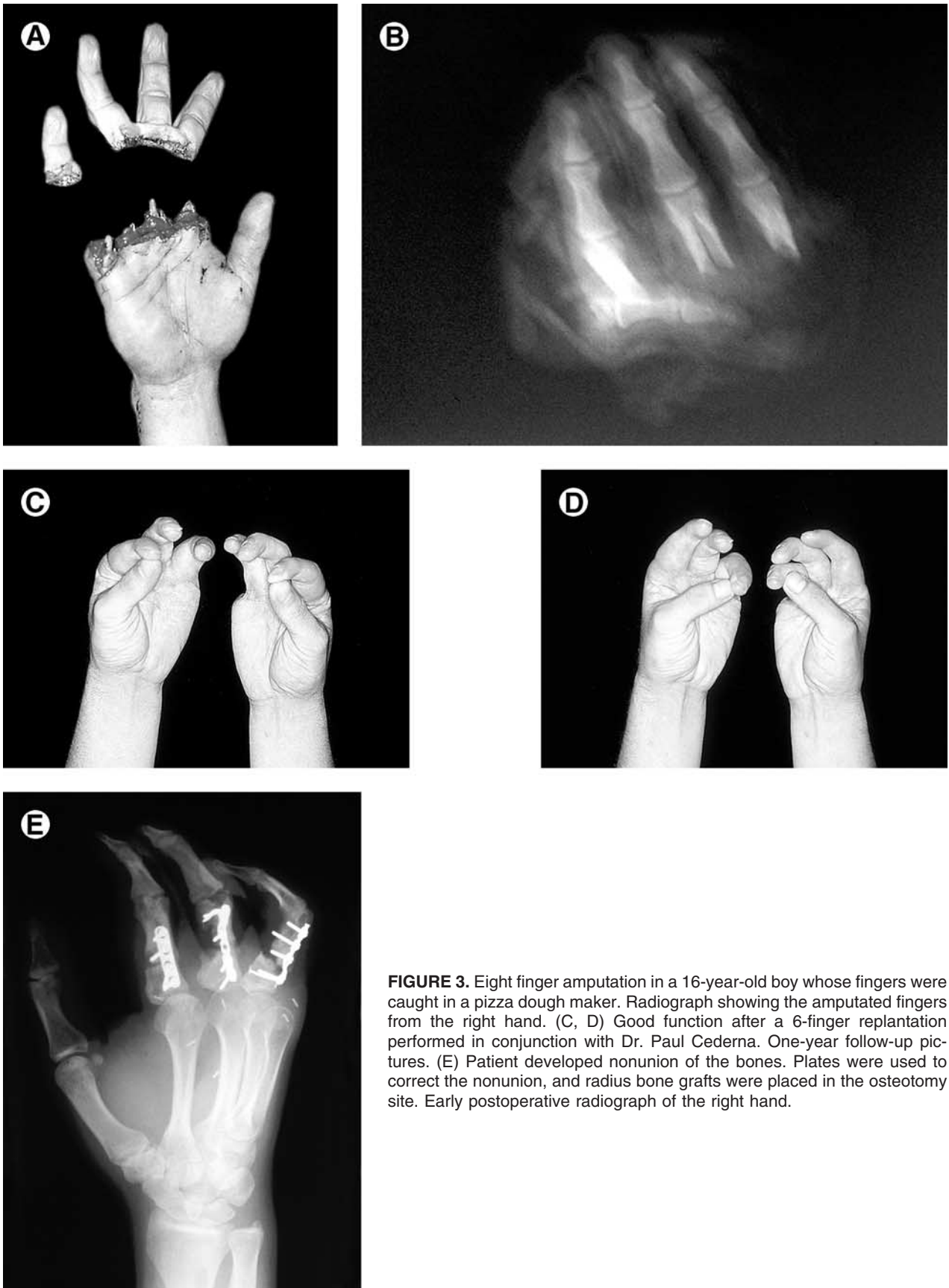
struction (Fig 3). Occasionally, the least injured digits must be replanted into different positions to maximize function and aesthetics. For example, if the thumb is severely crushed, a less damaged digit should be replanted to the thumb stump to optimize pinch and opposition functions.<sup>34</sup> For children, the indications for digit replantation are broad. Children are usually free of contraindicating factors such as chronic illness and smoking;<sup>33</sup> and they can easily adapt to digit replantations, resulting in excellent functional outcomes.<sup>22</sup> In addition, a child's self-esteem is often vulnerable to the psychologic stress that can result from hand deformities, making replantation

reconstruction an enormously rewarding procedure (Figs 4 and 5). Another absolute indication for replantation is any amputation at zone 3, 4, and 5 (Fig 6). Because the vessels are quite large, anastomosis of the arteries and veins is fairly easy. In addition, tendon function is favorable if early motion is started. A below-elbow replantation with adequate return of sensory and motor function is superior to a prosthesis.

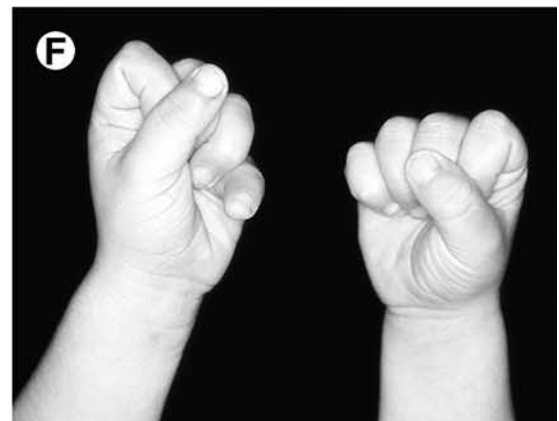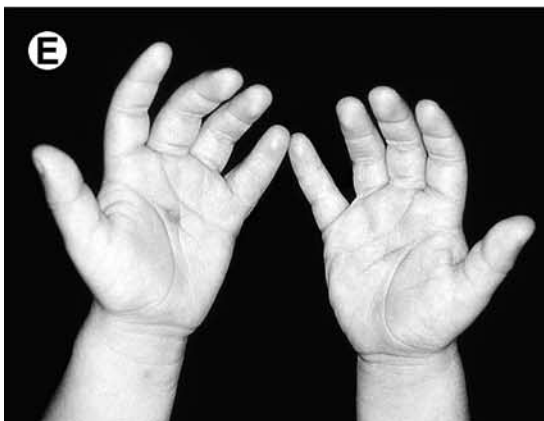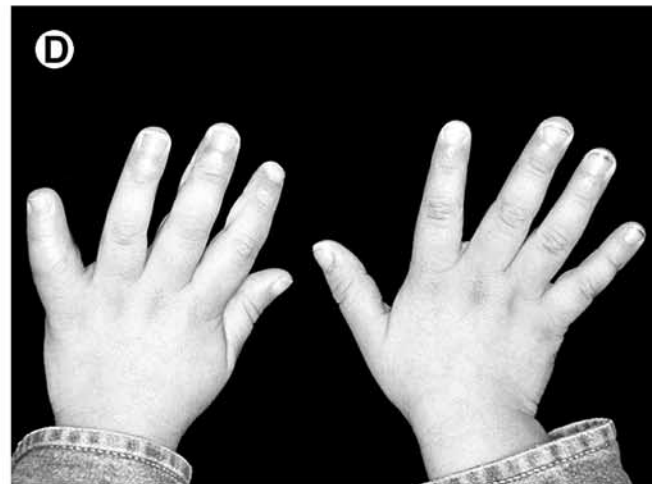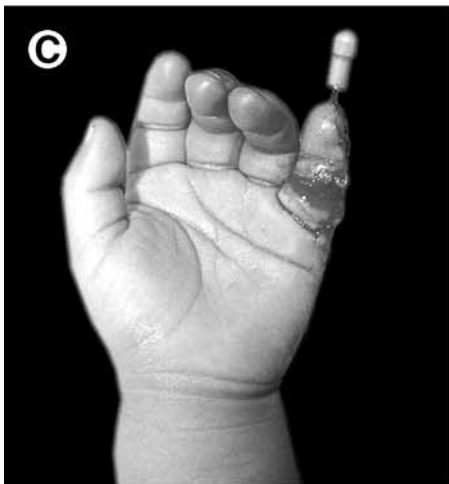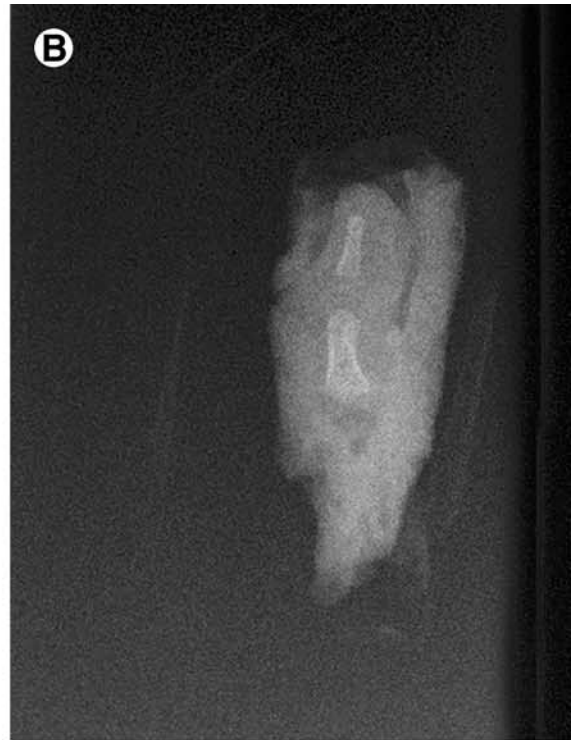
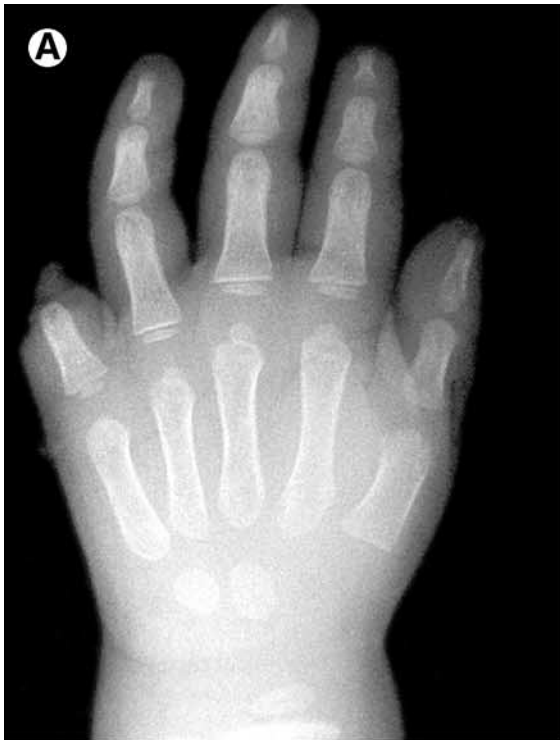Relative indications for digit replantation are amputations distal to the insertion of the flexor digitorum superficialis (FDS) and ring finger avulsion injuries.<sup>28</sup> Distal replantations are often technically successful in selected centers and are associated with



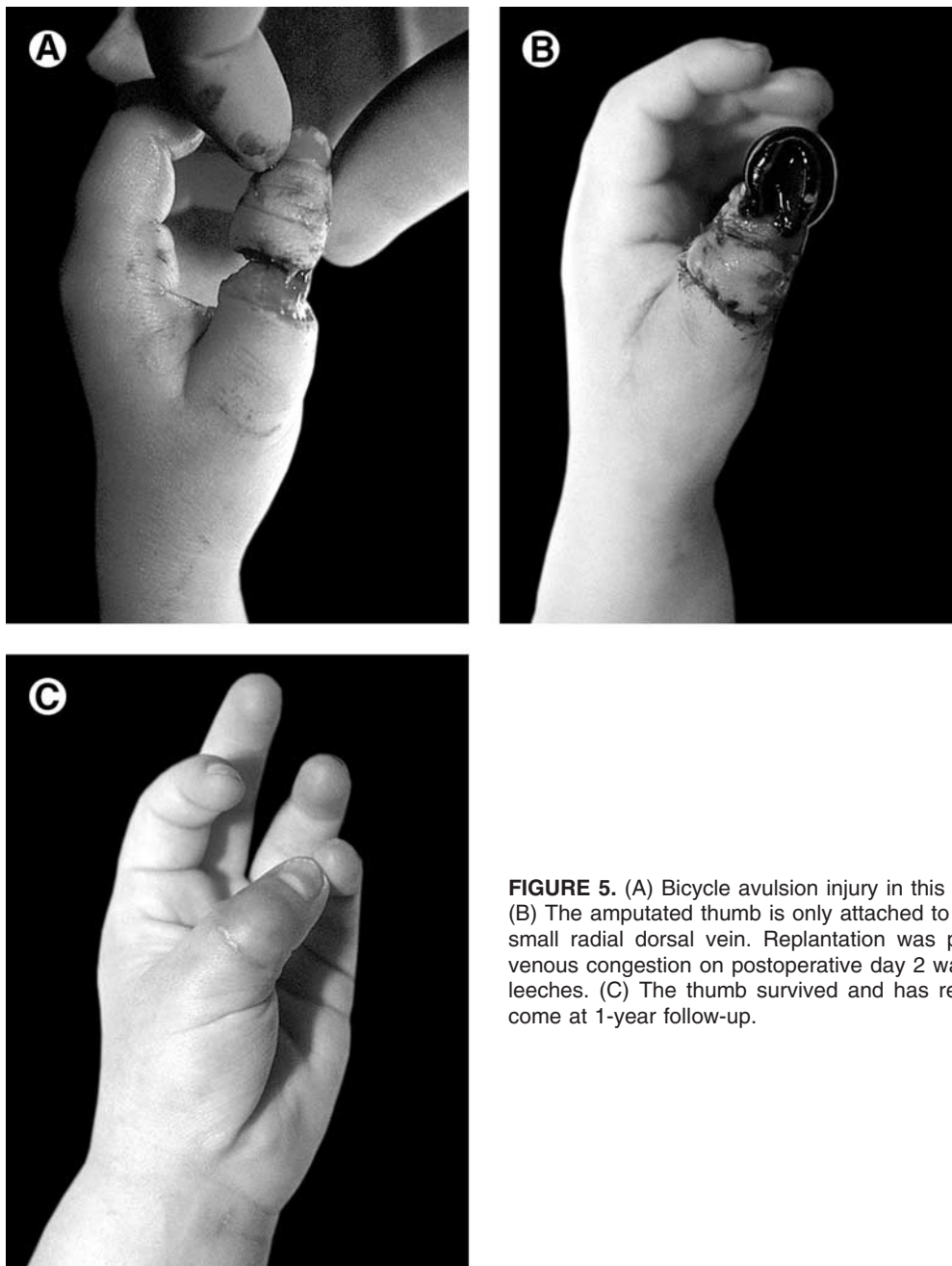
**FIGURE 2.** (A, B) Crush injury of the thumb through the interphalangeal joint. The amputated part was macerated, and not favorable for replantation. The patient is a mechanic and requested replantation. (C) Replantation was successful. Vein grafts were used for the arteries and veins. (D-F) Reasonable appearance but good functional outcome at 1-year follow-up. Two-point discrimination was 8 mm.



**FIGURE 3.** Eight finger amputation in a 16-year-old boy whose fingers were caught in a pizza dough maker. Radiograph showing the amputated fingers from the right hand. (C, D) Good function after a 6-finger replantation performed in conjunction with Dr. Paul Cederna. One-year follow-up pictures. (E) Patient developed nonunion of the bones. Plates were used to correct the nonunion, and radius bone grafts were placed in the osteotomy site. Early postoperative radiograph of the right hand.



**FIGURE 4.** (A) Radiograph of the hand showing amputation of the left little finger through the proximal interphalangeal joint in a 2-year-old boy. His finger was caught in the garage door and sustained a crushing amputation. (B) Radiograph of the amputated left little finger, which was wrapped in gauze. Although an amputation for this type of injury may be reasonable but not required in an adult, most surgeons will try to replant any amputated finger in a child. (C) The replant was successful. (D-F) One year after replanting the left little finger. The replanted finger is still edematous, but growing. He has adapted to the limited mobility of the little finger. There is no psychologic sequela in this child and his family.

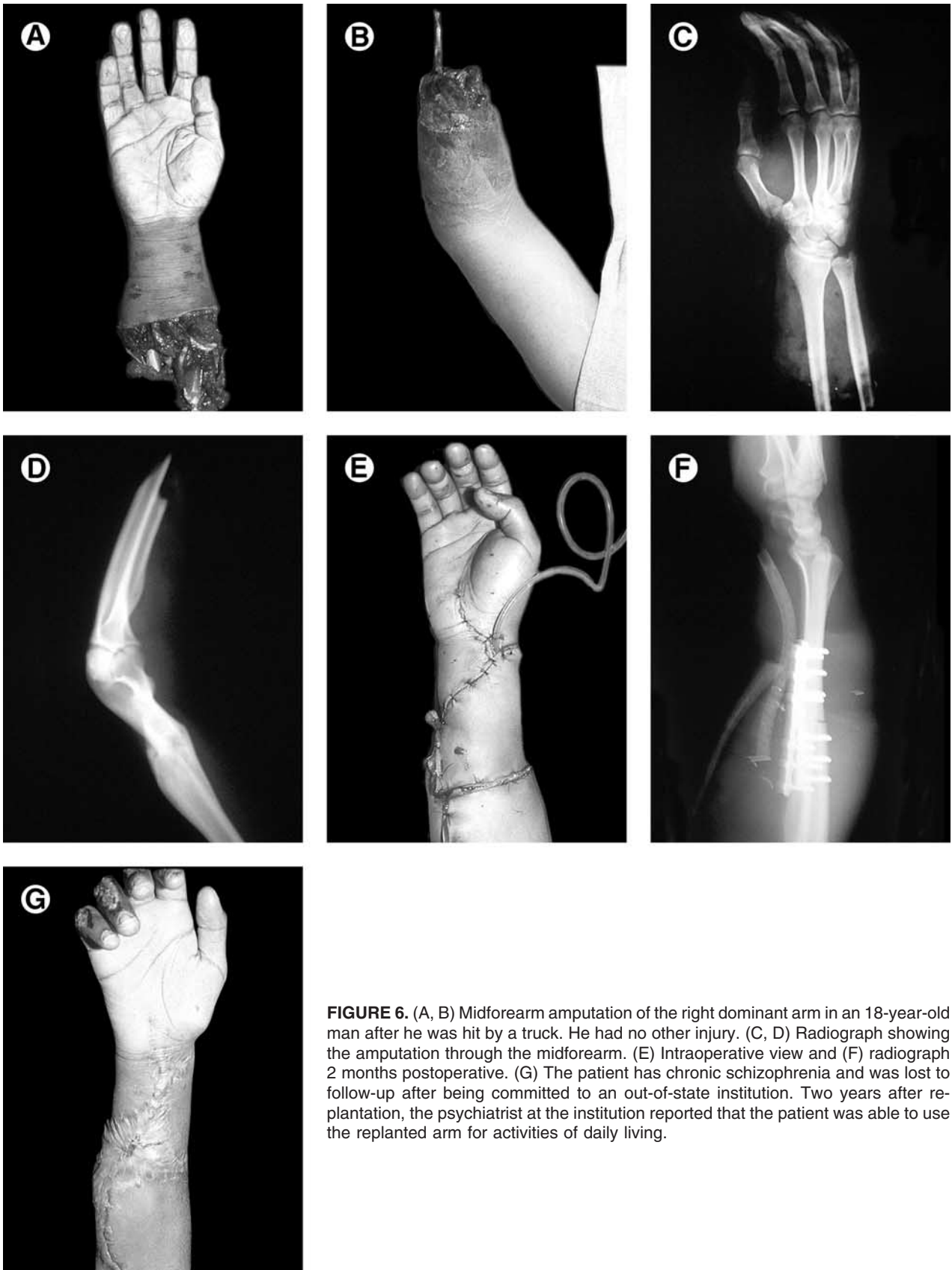

**FIGURE 5.** (A) Bicycle avulsion injury in this 1-year-old girl. (B) The amputated thumb is only attached to the hand by 1 small radial dorsal vein. Replantation was performed and venous congestion on postoperative day 2 was treated with leeches. (C) The thumb survived and has reasonable outcome at 1-year follow-up.

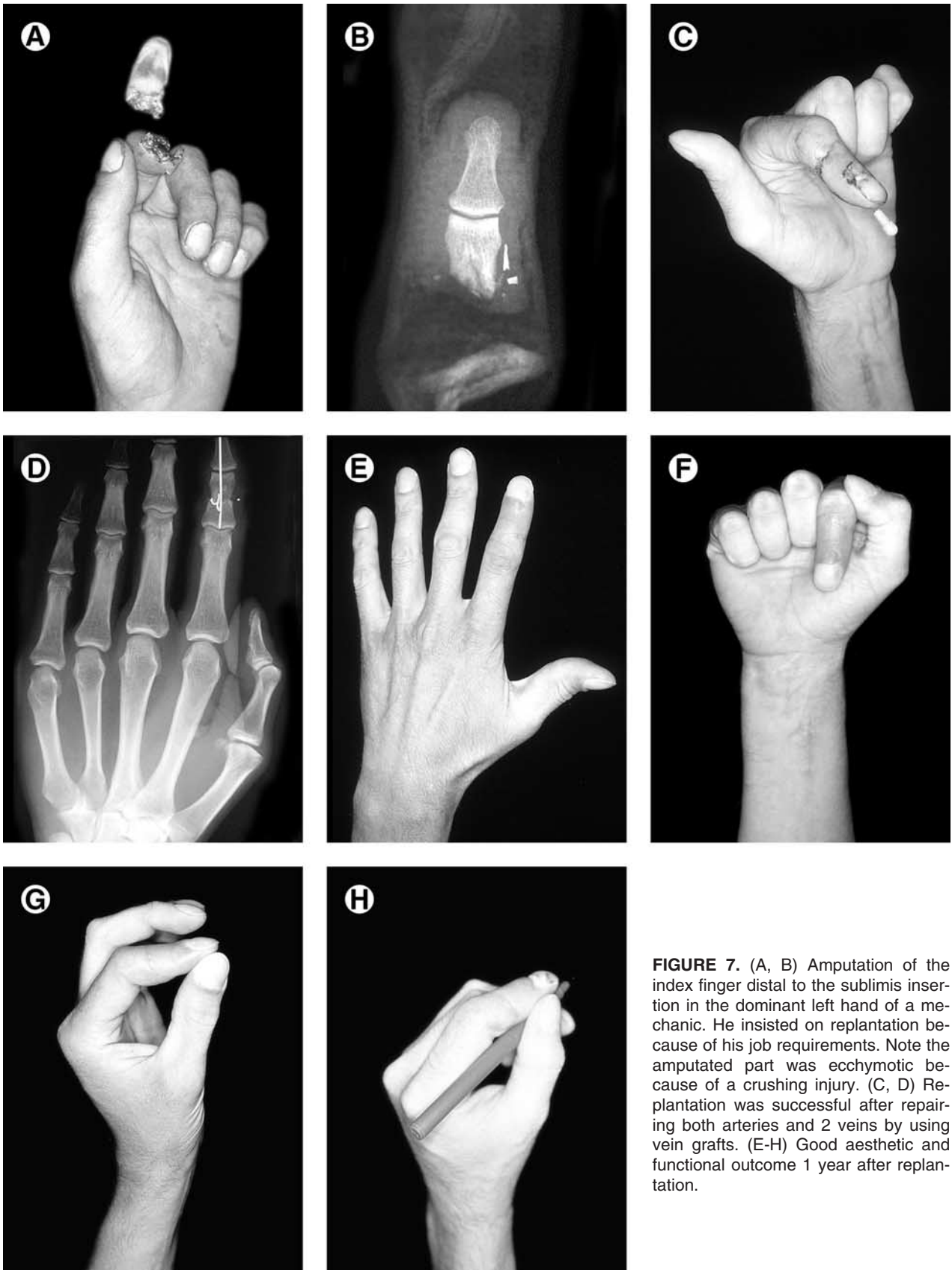
high patient satisfaction in function and aesthetics<sup>35</sup> (Figs 7 and 8). Regarding ring finger avulsion injuries, many surgeons advocate completing the amputation to preserve total hand function.<sup>36</sup> However, some microsurgeons are having success with Class I and Class II avulsion injuries.<sup>37,38</sup> Class III injuries (complete degloving or complete amputation) are more controversial (Fig 9). Although circulation may be reestablished, the chance of a functional outcome

must be considered. Patients with injured proximal interphalangeal joints and Class III avulsion injuries are less likely to have acceptable results with replantation owing to the disruption of the joint.<sup>38</sup>

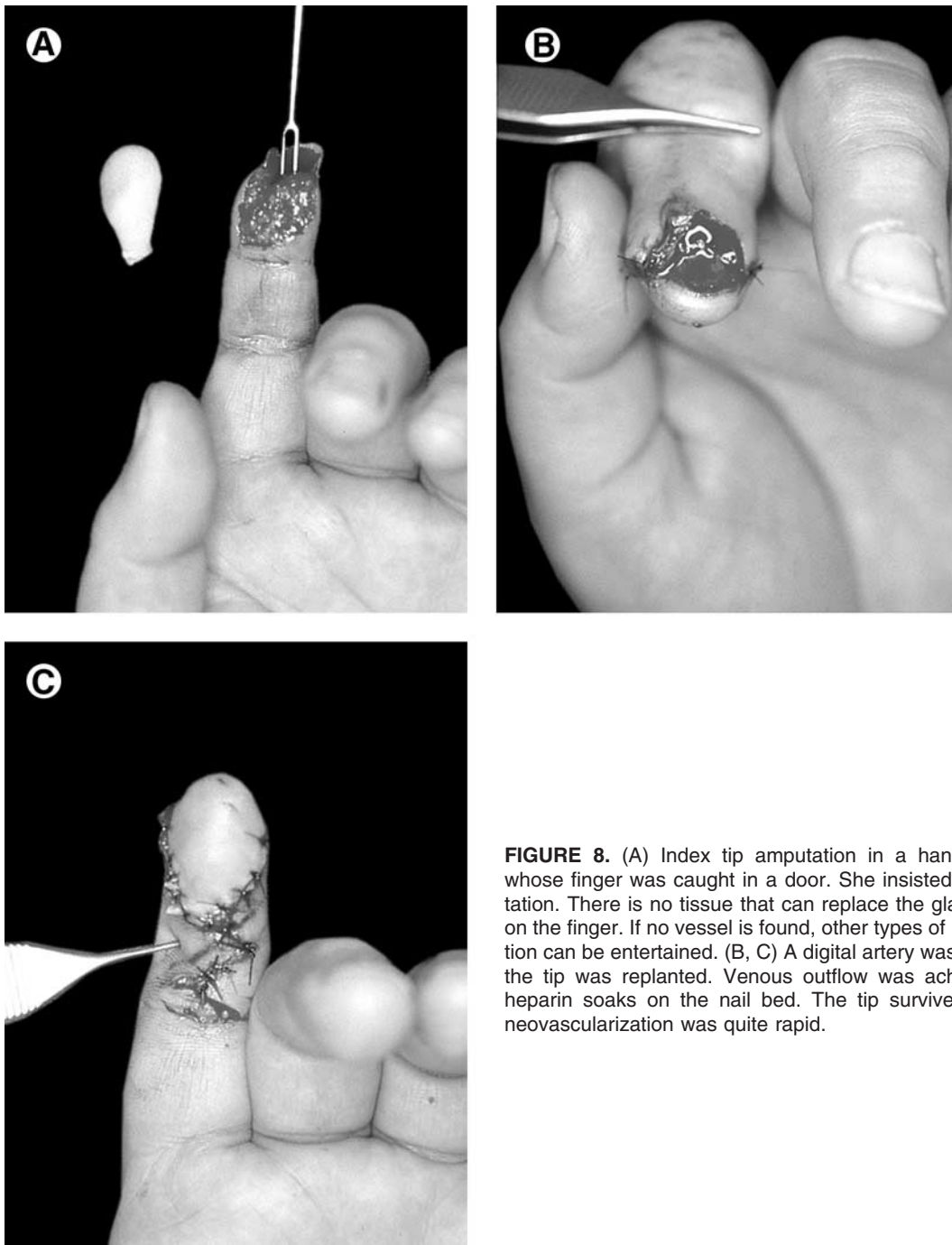
The absolute contraindications to upper-extremity replantation include any life-threatening injury that would preclude a prolonged anesthetic, chronic debilitating illness that would limit rehabilitation, major psychiatric illness, impaired function of the extremity



**FIGURE 6.** (A, B) Midforearm amputation of the right dominant arm in an 18-year-old man after he was hit by a truck. He had no other injury. (C, D) Radiograph showing the amputation through the midforearm. (E) Intraoperative view and (F) radiograph 2 months postoperative. (G) The patient has chronic schizophrenia and was lost to follow-up after being committed to an out-of-state institution. Two years after replantation, the psychiatrist at the institution reported that the patient was able to use the replanted arm for activities of daily living.



**FIGURE 7.** (A, B) Amputation of the index finger distal to the sublimis insertion in the dominant left hand of a mechanic. He insisted on replantation because of his job requirements. Note the amputated part was ecchymotic because of a crushing injury. (C, D) Replantation was successful after repairing both arteries and 2 veins by using vein grafts. (E-H) Good aesthetic and functional outcome 1 year after replantation.

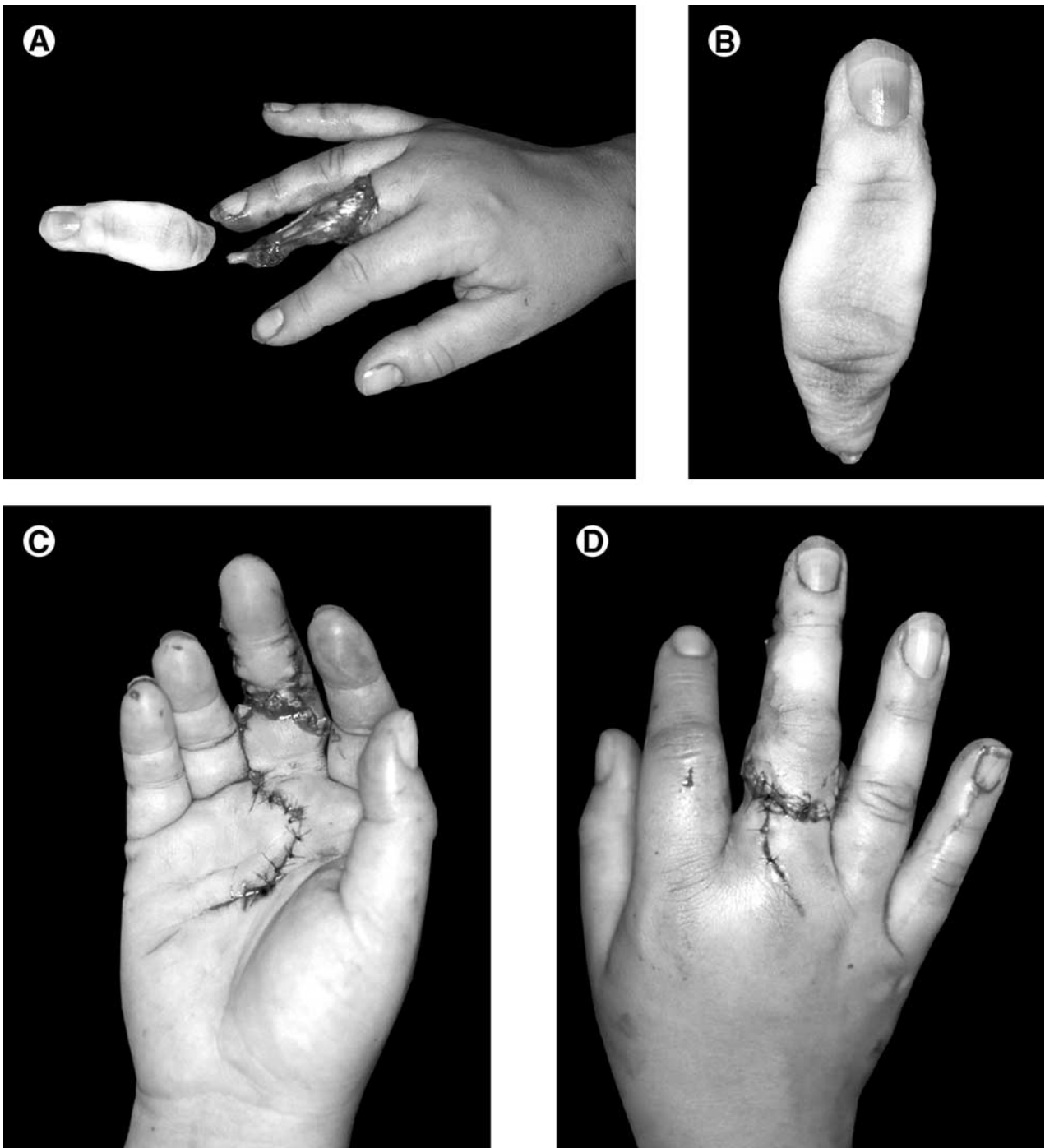


**FIGURE 8.** (A) Index tip amputation in a hand therapist whose finger was caught in a door. She insisted on replantation. There is no tissue that can replace the glabrous skin on the finger. If no vessel is found, other types of reconstruction can be entertained. (B, C) A digital artery was found and the tip was replanted. Venous outflow was achieved with heparin soaks on the nail bed. The tip survived because neovascularization was quite rapid.

from a previous injury or disease, profuse contamination of the extremity, or prolonged warm ischemia of the amputated tissue.<sup>39,40</sup> What constitutes prolonged warm ischemia is debatable and depends on the muscle mass involved, but the general recommendations are 6 to 8 hours for an extremity and 10 to 12 hours for a digit.<sup>40</sup> However, proper handling of the ampu-

tated tissue can extend the acceptable ischemia time beyond 24 hours.<sup>25</sup>

Relative contraindications to digit replantation are injuries through the proximal forearm and single digit amputations proximal to the insertion of the FDS because both have limited functional outcomes.<sup>28,38</sup> Replantation of a single digit amputation is contro-



**FIGURE 9.** (A, B) Ring avulsion injury in a 40-year-old woman when her finger was caught in a swing. (C, D) Immediate postoperative view after repairing both arteries and 3 veins. One-year postoperative pictures were lost, but she has 180° of active motion and 10-mm 2-point discrimination.

versial. If function is not obtained, the stiff and hypo- or hypersensitive digit may limit overall hand function more than a hand with an amputated digit.<sup>31,41</sup> The excellent functional and aesthetic results of ray

resection, especially of the index finger, must be weighed against the relatively unpredictable function of the isolated digital replantation. Other factors such as patient age should be assessed physiologically

rather than chronologically, with no predetermined age limit for replantation. Chronic medical conditions such as diabetes mellitus and chronic obstructive lung disease are not necessarily contraindications to surgery but warrant close postoperative follow-up.<sup>25</sup>

### SURGICAL TECHNIQUE

One of the most difficult procedures in hand surgery is upper-extremity replantation; the technical demand is high, the tissue condition is less optimal, the surgical time is long, and the timing is poor (often in the early mornings). Even with these difficult conditions, replantation is a rewarding procedure because there is so much to gain and little to lose for the patient, particularly when the indications are clear. The prior case illustrations showed that successful replantations can restore hand function that is difficult to match by any secondary procedures.

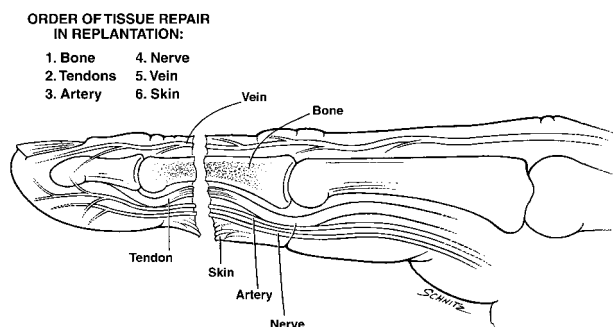
When a call is received for replantation, the surgeon needs to start assembling the appropriate personnel and equipment for the surgery. The operating room staff is notified so that they can allocate the necessary resources for the procedure. Once the patient arrives at the emergency room, basic trauma survey is undertaken to rule out other concomitant injuries. It is often difficult to have an adequate conversation with the patient in the chaos of the emergency room setting, but it is particularly important to spend a few quiet moments with the patient to inform him/her about the surgical procedure, the anticipated length of time off work, and the potential complications. The surgeon needs to listen to the patient about his/her job requirements and social issues. It is quite possible that replantation will be aborted at this point if the patient is unwilling or unable to invest the time and effort for a long postoperative rehabilitation process. On the other hand, the surgeon may be swayed to replant a finger that is amputated distal to the sublimis insertion or that is avulsed in a Class III ring avulsion injury when the patient has a definitive need or preference for replantation. The patient's perspective is rather important because the patient will need to live with his/her decision, and there is no role for arbitrarily amputating fingers or hands because the surgeon is unwilling to invest the effort to provide just care for the patient. If the technical expertise is unavailable, immediate transfer of a patient to a facility known for replantation expertise should be initiated.

When the decision has been made to proceed with replantation, the operating room staff is notified to proceed with setting up the operating room for surgery. Once the surgeon is committed to take a patient to the operating room for replantation, the surgeon needs to have the mind-set that he/she is going to do the best to make it a successful outcome. A half-hearted effort of going to the operating room just to look is doomed to failure. Replantation is probably the most difficult procedure in reconstructive surgery, and any lingering doubts about whether the effort is worthwhile will make the surgeon entertain an easier amputation option.

Although the patient is being prepared for surgery, the amputated part is taken to the operating room, where it is cleansed with saline and diluted betadine solution. The amputated part is examined under the microscope. A bilateral midaxial incision to identify the nerves and arteries is ideal. The dorsal skin flap is elevated off the extensor mechanism and the subcutaneous venous plexus is isolated. The nerves and vessels are tagged with 6-0 prolene suture for easy retrieval. About 1 or 2 mm of the extensor and flexor tendon ends are sharply excised with an 11-blade. The bone is shortened by about 2 mm. Excessive shortening of the bone should be avoided because, unless the amputation is sharp and clean (unusual situation), most replantation efforts require vein grafts for tensionless repair and for bypassing vasospastic segments of arteries at the amputation site.

While the part dissection is performed, the patient is prepared for surgery. If reliable regional anesthetic expertise is available, an axillary block is preferred for its vasodilatory effect. For multiple finger or proximal hand amputations requiring prolonged surgical time, a general anesthesia supplemented with an axillary block is preferred. Similar dissection is performed in the hand to identify appropriate structures. Before hand exsanguination, the volar wrist veins are marked out. Volar wrist veins and dorsal foot veins are similar in caliber to digital vessels, whereas saphenous veins are a better fit for vessels proximal to the hand.

Each surgeon has an individual preference for the sequence of repair in replantation (Fig 10). In general, bone fixation should be performed first. Cross K-wires are expeditious, but occasionally in single or 2-finger replantation, when surgeon fatigue is not as much of a factor, a 4-hole plate for more stable fixation can be



**FIGURE 10.** A schematic representation of the order for tissue repair during replantation.

placed so that earlier motion can be started. Surgeon fatigue is definitely an issue in multiple finger replantations, particularly when an alternating team is not available. The whole procedure needs to be performed efficiently and predictably.

After bony fixation, the flexor tendons are repaired with a 4-strand Ethibond suture repair. In zone II injury, repair of only the profundus tendon may be undertaken to avoid adhesions between the superficialis and profundus tendon suture lines. The extensor tendon is repaired next by using a horizontal mattress stitch, and the intrinsic tendons, if available, are repaired in a similar fashion.

The arteries are repaired next. In some situations, the amputation is a clean cut, and the trauma to the arteries is minimal. In these situations, primary anastomosis is straightforward. If there is any question about the feasibility of primary anastomosis, a vein graft from the volar wrist may be harvested. If a vein graft is used, there is more latitude in excising more of the artery until the lumen appears uninjured. Often the proximal lumen is spastic, and one needs to continue excising the damaged artery until a clear spurt is seen from the proximal lumen.

There is often a question as to whether to repair 1 or both digital arteries. The repair of both arteries gives added assurance of maintaining adequate inflow. Despite the best efforts, digital artery repair does thrombose because the lumen is small (often less than 1 mm in external diameter) and the zone of injury is quite large. Taking added measures, including repair of all possible arteries and veins, increases the chances of success. The digital nerves are then repaired with 2 or 3 microsutures because they are located in the same surgical field.

Once the artery and nerves are repaired, the clamps are left on the arteries while the veins are repaired dorsally. Vein grafts are often not needed for venous anastomosis. Sometimes, ligating the venous branches can increase the length of the veins for a tension-free repair. Venous anastomosis is probably the most difficult facet of replantation. The veins are often collapsed and difficult to find. An attempt should be made to repair as many veins as possible before releasing the arterial clamps. If the veins are small and difficult to trace, the arterial clamps can be released, and the veins will enlarge and will be easier to find. However, diffuse bleeding from the skin edges makes venous anastomosis quite cumbersome, and repair of the veins without arterial inflow is often easier. Before releasing the arterial clamp, a bolus of 3,000 U heparin is given intravenously and maintained at 800 U/hr postoperatively for 5 days in adults. In addition, Dextran 40 (Scarborough, Ontario, Canada) at 25 mL is given for 5 days. Replantation, unlike free-flap procedures, deals with damaged tissues and all pharmacologic support should be used.

The skin is closed loosely, and a volar splint is applied. The finger often takes a while to pink-up, depending on the length of the ischemic time. But once the splint is applied, the finger usually becomes rather warm on arrival to the recovery room. A heat lamp is placed over the hand, and room temperature should be maintained over 70°F.

#### TECHNICAL VARIATIONS

Occasionally, skin may be deficient over the volar surface of the finger. In these cases, a venous flap harvested from the volar wrist as a flow-through flap when reconstructing the digital arteries is helpful. Dr. Pederson has suggested this option, and it is a good option for adding supple skin over the volar finger.<sup>42</sup> This technique is rarely used, but can be an elegant option for a difficult problem.

Zone I replantation is a very gratifying procedure for the patient and the surgeon when it is successful. However, finding venous outflow is difficult. Relying on leeches or heparin soaks on the nail bed is often insufficient to ensure survival. One often finds zone I replantations marginally perfused for 5 days before necrosing. A technical variation for zone I replant is to use 1 of the arteries as an outflow. A vein graft connects the artery with a dorsal vein and establishes

an arterial venous loop. Because the tissue is small, this arterial venous loop maintains perfusion and buys time until neovascularization to the fingertip is formed.

### POSTOPERATIVE CARE AND COMPLICATIONS

Patients are admitted to the hospital for 5 days after replantation. Full pharmacologic support is continued for 5 days, which includes low-dose heparin at 800 U/hr and dextran 40 at 25 mL/hr. Unless there is excessive bleeding from the wound, the dressing is not changed for at least 5 days. The stress and discomfort associated with dressing changes may cause vasospasm and clot off the vessels. We have had a couple of instances when the dressing was changed early in uncomplicated replantation cases, resulting in vasospastic episodes and cessation of blood flow into the replanted part.

Arterial problems are rather uncommon given the aggressive approach in using vein grafts for arterial reconstruction, but venous outflow problems are not unusual. Occasionally, leeches or heparin soaks are applied to the nail bed to promote blood outflow. Leeches are applied every 6 hours. The anticoagulant, hirudin, secreted by the leeches, is sufficient to keep the replanted part bleeding for at least 6 hours. A third-generation cephalosporin is given intravenously to cover *Aeromonas hydrophilia*, a gram-negative bacteria that is part of the normal intestinal flora in leeches. When the venous congestion is not severe, or in fingertip replantation when the part is small, placement of normal-strength heparin on the nail bed is a better option. The nail is removed, and the nail bed is rubbed with straight heparin with a cotton swab every hour.

Early complications after replantation are uncommon, other than the occasional failure to salvage the replanted parts. We rely on visual examination for monitoring the replanted digit, but occasionally we will use a temperature probe to confirm the clinical impression. A temperature of 32°C or less in the replanted part is a poor prognostic finding. Late complications are rather common, consisting of stiffness of the finger (occurs in varying severity), inadequate nerve regeneration, and malunion or nonunion of the bone. Stiffness of the finger is often secondary to tendon adhesion, particularly in zone II flexor tendon repairs. Tenolysis is extremely difficult when scarring and adhesions obscure all anatomic boundaries. The

risk for devascularizing the replanted finger is also a possibility. One should be somewhat reluctant to perform tenolysis in replanted fingers, unless the replanted fingers are essentially functionless.

### OUTCOMES

Assessment of upper-extremity replantations is difficult because it is not feasible to design a randomized clinical trial. Results are assessed by case series, which are inherently flawed because of the inability to control for known and unknown confounding variables. However, common themes run through these case series that can be useful for predicting the outcomes of replantation surgery.

In general, the survival of replantations is dependent on the patients age, being worst in the first and seventh decades and best in the second decade of life.<sup>22,41</sup> Sharp or guillotine injuries have better survival rates than crush injuries, and injuries proximal and distal to the no man's land of the flexor tendon system have better functional results than those involving zone II.<sup>38,41,43,44</sup> The average return to work time for patients with digit amputations is 1.9 and 3.7 months for injuries distal and proximal to the FDS, respectively.<sup>22</sup> However, rehabilitation and time off from work can last longer than 1 year in patients with arm replantations.<sup>28</sup> Cold intolerance is a common complaint in all replantations,<sup>14,22,45</sup> though the incidence in children may be less.<sup>46</sup> For children, the growth of the digit is often a concern, but growth does not appear impaired in the majority of patients if the growth center is not injured.<sup>46</sup>

Specific survival rates for digit replantation show a sharp increase since the 1970s. Initial survival rates in 1970 were 26.8%, but by 1977 the rates improved to 87.5%.<sup>25,41</sup> Currently, survival rates of over 90% are often reported. However, several factors impact survival results, such as the mechanism of injury and the age of the patient. For example, the University of Louisville had an overall success rate of 90% from 1970 to 1978, however, this dropped to 85% when the cases were limited to those aged 16 years or younger.<sup>46</sup> When the younger cohort results were stratified by the type of injury, survival was highest in guillotine amputations (94%) and lowest in avulsion injuries (74%).<sup>46</sup> In addition, Duke University, Durham, NC, found a similar age effect on survival because their rates from 1973 to 1982 dropped from

86% overall to less than 70% in those between 10 weeks and 10 years of age.<sup>22</sup>

Fewer case series are reported for above-elbow amputations compared with digit replantations, and the survival is more dependent on the muscle mass of the amputated tissue and the warm ischemia time rather than the microsurgical skill of the surgeon. In addition, the number of replantation successes may be biased because failures are less likely to be reported in the literature. Nevertheless, of the case series reported, successful replantation rates have increased approximately 10% each decade, starting at 60% in 1972, followed by 70% in 1980, and greater than 80% in 1990.<sup>14,47,48</sup> However, survival rates are incomplete measures of outcomes without information on sensibility and function.

Regaining sensibility does not appear to be dependent on which digit is amputated or the time lapse before revascularization.<sup>45</sup> Results of 2-point discrimination postoperatively are varied. Two studies have reported a 50% return of 2-point discrimination of 15 mm or less,<sup>43,45</sup> and 2 centers have reported a 90% or greater return of 15 mm or less.<sup>23,46</sup> In these case series, 26% to 39% of patients regained 6 mm or less of 2-point discrimination,<sup>45,46</sup> with an average of 8 to 11.7 mm in adults.<sup>22,23</sup> For above-elbow limb amputations, the majority obtain protective sensibility, but regaining 2-point sensibility is rare.<sup>30,48</sup> Individual surgeon and patient factors that are not controlled for in these case series most likely account for these inconsistencies.

The functional results of digit replantations also have inconsistencies, but common elements are associated with suboptimal results. Flexor tendon adherence is a common impairment to functional recovery, and, therefore, injuries through zone II are often associated with poor digit mobility.<sup>22,23,43</sup> For example, Duke University has reported an average of 82° proximal interphalangeal joint motion in amputations distal to the FDS and 35° in those involving the FDS.<sup>22</sup> In addition, outcomes are dependent on the type of injury, with worse results in avulsion compared with guillotine mechanisms.<sup>46</sup> For upper-limb amputations, chances of regaining useful control of the forearm, wrist, and hand improve with more distal amputations, and many will require tendon transfers for adequate elbow function.<sup>48</sup>

In this current era of escalating health care costs, one must ask whether the outcomes from microsurgi-

cal replantation are justifiable. Most cost studies are incomplete, with little data on quality-of-life issues. A cost-effectiveness analysis of digit replantation is complicated because the quality of life gained will be greatly affected by the digit involved, the level of the amputation, and the occupation of the individual. However, the current data on replantation costs show that this procedure is capturing a very limited portion of health care resources.<sup>24,49</sup> Therefore, minimal improvements in a patient's quality of life would make replantation a cost-effective intervention. Hopefully, future research will investigate patient satisfaction and changes in life quality in this patient population.

### CONCLUSION

Since the beginning of replantation surgery, efforts have been aimed toward improving microvascular anastomoses through pharmacologic and technical advancements. As survival rates have consistently reached the 90% mark, efforts have been redirected toward improving function. In addition, researchers have made significant strides in transplantation surgery, and progress will continue with the advent of less-toxic immunotherapy to channel the era of transplantation in hand surgery. Significant advances in extremity reconstruction may come through stem cell research.

Currently, the most daunting task for replantation surgeons is the unpredictable revascularization of the amputated part, even with the best microsurgical efforts. Future research may reveal growth factors that can expedite neovascularization of the amputated parts, even when the condition of the vascular repair is less than optimal. With more predictable survival in replantation and less tedious surgical procedures, the indications for replantation will likely expand.

### REFERENCES

1. Littler JW. On making a thumb: one hundred years of surgical effort. *J Hand Surg* 1976;1:35-51.
2. Balfour W. Two cases, with observation, demonstrative of the powers of nature to reunite parts which have been, by accident, totally separated from the animal system. *Edinburgh Med Surg J* 1814;10:421-430.
3. Gillies H. Autograft of amputated digit. *Lancet* 1940;1:1002-1003.
4. Gordon S. Autograft of amputated thumb. *Lancet* 1944;2:823.
5. Kleinert HE, Kasdan ML, Romero JL. Small blood-vessel anastomosis for salvage of severely injured upper extremity. *J Bone Joint Surg Am* 1963;45A:788-796.
6. O'Brien BM, MacLeod AM, Miller GD, Newing RK, Hay-

- hurst JW, Morrison WA. Clinical replantation of digits. *Plast Reconstr Surg* 1973;52:490-502.
7. Replantation surgery in China. Report of the American replantation mission to China. *Plast Reconstr Surg* 1973;52:476-489.
  8. Ch'en CW, Ch'ien YC, Pao YS, Lin CT. Further experiences in the restoration of amputated limbs. Report of two cases. *Chin Med J (Engl)* 1965;84:225-231.
  9. Ch'en CW, Ch'ien YC, Pao YS. Salvage of the forearm following complete traumatic amputation. Report of a case. *Chin Med J (Engl)* 1963;82:632-638.
  10. Successful restoration of severed hand. *Chin Med J (Engl)* 1963;82:618.
  11. Malt RA, McKhann CF. Replantation of severed arms. *JAMA* 1964;189:716-722.
  12. Buncke HJ, Schulz WP. Experimental digital amputation and reimplantation. *Plast Reconstr Surg* 1965;36:62-70.
  13. Kleinert HE, Jablon M, Tsai TM. An overview of replantation and results of 347 replants in 245 patients. *J Trauma* 1980;20:390-398.
  14. Komatsu S, Tamai S. Successful replantation of a completely cut-off thumb: case report. *Plast Reconstr Surg* 1968;42:374-377.
  15. Cobbett JR. Free digital transfer. Report of a case of transfer of a great toe to replace an amputated thumb. *J Bone Joint Surg Br* 1969;51B:677-679.
  16. Winfrey EW, Foster JH. Low molecular weight dextran in small artery surgery. *Arch Surg* 1964;88:100-104.
  17. Ch'ien YC, Ch'en CW, Lin CT, Pao YS. Some problems concerning small vessel anastomosis in the reattachment of complete traumatic amputations. *Chin Med J (Engl)* 1966;85:79-86.
  18. O'Brien BM. Inaugural William Manchester lecture. The influence of microsurgery research on plastic and reconstructive surgery. *Aust N Z J Surg* 1992;62:680-690.
  19. Gorman A, Harry Buncke Jr. Call him the father of microsurgery. *Plast Surg News* 2001;12:5,16.
  20. Replantation of severed limbs. Analysis of 40 cases. *Chin Med J (Engl)* 1975;1:265-274.
  21. Replantation of severed fingers. Clinical experience in 217 cases involving 373 severed fingers. *Chin Med J (Engl)* 1975;1:184-196.
  22. Urbaniak JR, Roth JH, Nunley JA, Goldner RD, Koman LA. The results of replantation after amputation of a single finger. *J Bone Joint Surg Am* 1985;67A:611-619.
  23. Morrison WA, O'Brien BM, MacLeod AM. Evaluation of digital replantation—a review of 100 cases. *Orthop Clin North Am* 1977;8:295-318.
  24. Chung KC, Kowalski CP, Walters MR. Finger replantation in the United States: rates and resource use from the 1996 Healthcare Cost and Utilization Project. *J Hand Surg [Am]* 2000;25A:1038-1042.
  25. Kleinert HE, Juhala CA, Tsai TM, VanBeck A. Digital replantation—selection, technique, and results. *Orthop Clin North Am* 1977;8:309-318.
  26. Tamai S. History of microsurgery—from the beginning until the end of the 1970s. *Microsurgery* 1993;14:6-13.
  27. Bieber EJ, Wood MB, Cooney WP, Amadio PC. Thumb avulsion: results of replantation/revascularization. *J Hand Surg [Am]* 1987;12A:786-790.
  28. Goldner RD, Fitch RD, Nunley JA, Aitken MS, Urbaniak JR. Demographics and replantation. *J Hand Surg [Am]* 1987;12A:961-965.
  29. Burton RI. Problems in the evaluation of results from replantation surgery. *Orthop Clin North Am* 1981;12:909-913.
  30. Haws MJ, Erdmann D, Brown RE. Above-elbow arm replantation during pregnancy. *Ann Plast Surg* 1996;36:93-96.
  31. Manktelow RT. What are the indications for digital replantation? *Ann Plast Surg* 1978;1:336-337.
  32. Chung KC, Wei FC. An outcome study of thumb reconstruction using microvascular toe transfer. *J Hand Surg [Am]* 2000;25A:651-658.
  33. Raimondi PL, Petrolati M, Delaria G. Replantation of large segments in children. *Hand Clin* 2000;16:547-561.
  34. Soucacos PN, Beris AE, Malizos KN, Vlatsoy C, Soucacos PK, Georgoulis AD. Transpositional microsurgery in multiple digital amputations. *Microsurgery* 1994;15:469-473.
  35. Yamano Y. Replantation of the amputated distal part of the fingers. *J Hand Surg [Am]* 1985;10A:211-218.
  36. Bevin AG, Chase RA. The management of ring avulsion injuries and associated conditions in the hand. *Plast Reconstr Surg* 1963;32:391-400.
  37. Tsai TM, Manstein C, DuBou R, Wolff TW, Kutz JE, Kleinert HE. Primary microsurgical repair of ring avulsion amputation injuries. *J Hand Surg [Am]* 1984;9A:68-72.
  38. Urbaniak JR, Evans JP, Bright DS. Microvascular management of ring avulsion injuries. *J Hand Surg [Am]* 1981;6:25-30.
  39. Kutz JE, Hanel D, Schecker L, Lopez G. Upper extremity replantation. *Orthop Clin North Am* 1983;14:873-891.
  40. Gold AH, Lee GW. Upper extremity replantation: current concepts and patient selection. *J Trauma* 1981;21:551-557.
  41. Weiland AJ, Villarreal-Rios A, Kleinert HE, Kutz J, Atasoy E, Lister G. Replantation of digits and hands: analysis of surgical techniques and functional results in 71 patients with 86 replantations. *J Hand Surg* 1977;2:1-12.
  42. Pederson WC. Upper extremity microsurgery. *Plast Reconstr Surg* 2000;107:1524-1537.
  43. Tami S, Hori Y, Fukui A, Shimizu T. Finger replantation. *Int Surg* 1981;66:9-12.
  44. Soucacos PN, Beris AE, Touliatos AS, Vekris M, Pakos S, Varitimidis S. Current indications for single digit replantation. *Orthop Scand* 1995;(Suppl)264:12-15.
  45. Gelberman RH, Urbaniak JR, Bright DS, Levin LS. Digital sensibility following replantation. *J Hand Surg [Am]* 1978;3:313-319.
  46. Jaeger SH, Tsai TM, Kleiner HE. Upper extremity replantation in children. *Orthop Clin North Am* 1981;12:897-907.
  47. Malt RA, Remensnyder JP, Harris WH. Long-term utility of replanted arms. *Ann Surg* 1972;176:334-342.
  48. Wood MB, Cooney WP. Above elbow limb replantation: functional results. *J Hand Surg [Am]* 1986;11A:682-689.
  49. Gaul JS. Identifiable costs and tangible benefits resulting from the treatment of acute injuries of the hand. *J Hand Surg [Am]* 1987;12A:966-970.