

Aesthetic and Reconstruction Considerations in Oncologic Breast Surgery

Joon Y Choi, MD, Amy K Alderman, MD, Lisa Ann Newman, MD, MPH, FACS

Breast cancer is the most common malignancy seen in women in the US; with an age-adjusted incidence of more than 120 per 100,000 American women, it is reported to affect at least 1 in 9 over an 85-year lifetime.^{1,2} Advances in breast health awareness, with improved screening, earlier detection of disease, and more effective systemic therapy, have resulted in considerable declines in breast cancer mortality rates, by approximately 2% per year.³ These improvements in outcomes have motivated efforts to offer comparable progress in survivorship issues such as quality of life and aesthetically enhanced breast cancer surgery. Breast conservation surgery (BCS) and breast reconstruction represent major examples of these efforts.

BCS has been definitively shown to be an oncologically safe treatment for breast cancer in multiple prospective randomized trials conducted internationally,⁴⁻⁷ and it has been deemed by the National Institutes of Health preferable to mastectomy in appropriately selected patients because of the cosmetic benefits.⁸ For patients who undergo mastectomy, the technology of breast reconstruction can reverse some of the psychosocial and physical impact of this disfiguring operation,⁹ and access barriers related to cost have been partly overcome by the 1998 Women's Health and Cancer Rights Act, a federal law mandating insurance coverage for mastectomy reconstruction. Nonetheless, several reports have indicated that both BCS and breast reconstruction are underused in the US.¹⁰⁻¹³ There are additional, easily overlooked concepts in general surgical and reconstructive techniques that can improve the symmetry, comfort, and appearance of patients undergoing all forms of breast cancer surgery. The goal of this review article was to summarize some of the preoperative, intraoperative,

and postoperative considerations that may enhance the aesthetic results and physical well being of surgically treated breast cancer patients.

Preoperative considerations

Diagnostic biopsy technique

When feasible, a percutaneous needle biopsy is the preferred method of establishing a breast cancer diagnosis in comparison with an open surgical biopsy. This maneuver offers the patient and the surgeon an opportunity to plan a more comprehensive approach to cancer-directed breast and axillary surgery in a single procedure. Up to 50% of open, surgical diagnostic biopsies that reveal cancer have positive margins, necessitating reexcision if the patient wants BCS¹⁴; the reexcision lumpectomy can result in an increased total volume of resected breast tissue compared with a single-stage lumpectomy performed for a needle biopsy-proved cancer.

Several studies¹⁵⁻²¹ have demonstrated that lumpectomies are more likely to be margin-negative when the breast cancer diagnosis was previously documented by percutaneous needle biopsy as opposed to open surgical diagnostic biopsy. Core needle biopsies are more accurate than fine needle aspirates, and they have the advantage of providing adequate tissue for determining whether or not the lesion has an invasive histology. Core needle biopsies can be done freehand for palpable lesions, or they can be performed with stereotactic mammography or ultrasonography guidance for nonpalpable lesions. But accurate determination of the breast condition is clearly the first priority, so an open surgical diagnostic biopsy will remain necessary when adequate needle biopsy equipment is unavailable and when the needle biopsy reveals a nondiagnostic, discordant, or high-risk histopathology (such as atypical hyperplasia).

Another advantage of the percutaneous needle biopsy is related to preservation of neoadjuvant systemic therapy treatment options. Downstaging of breast cancer with preoperative chemotherapy has been shown to be oncologically safe; it allows the multidisciplinary management team to evaluate chemosensitivity in vivo, and it increases the likelihood of a successful lumpectomy.²²

Competing Interests Declared: None.

Received December 16, 2005; Revised February 15, 2006; Accepted February 17, 2006.

From the Division of Surgical Oncology, Department of Surgery, University of Michigan, Ann Arbor, MI.

Correspondence address: Lisa Ann Newman, MD, University of Michigan, Division of Surgical Oncology, 3308 Cancer Center, 1500 E Medical Center Dr, Ann Arbor, MI 48109-0932.

When the primary breast tumor has been excised for diagnostic surgical biopsy, there is no longer a focus of measurable disease that can be monitored to follow response to induction chemotherapy or endocrine therapy.

If a percutaneous needle biopsy has been performed for a nonpalpable, image-detected lesion, it is imperative that some radiopaque clip is inserted at the biopsy site. Multiple core biopsies (especially if vacuum suction-assisted) can result in complete extraction of the target lesion, and a clip will serve as a marker for any subsequent surgical resection needs. For larger lesions that are potential neoadjuvant chemotherapy candidates, a clip will be necessary in the event of a complete clinical response, so that the future lumpectomy site can be identified. Lesions that have associated microcalcifications will not require clip insertion.

Reconstruction is also aided by percutaneous needle biopsy; it usually prevents the need for open surgical biopsy. The open biopsy sites can limit flexibility in the orientation of the mastectomy resection, which can potentially impair aesthetic outcomes. In expander and implant reconstruction, open biopsy sites that cannot be incorporated into the nipple-areolar resection may lead to higher complication rates from tissue necrosis because of compromised tissue vascularity in the skin bridge located between the mastectomy and biopsy scar.

Avoiding hematoma formation

Avoidance of a breast hematoma begins during the preoperative planning phase. Hematomas that complicate a needle biopsy can considerably compromise cosmetic outcomes with BCS, necessitating resection of a larger volume of breast tissue. So patients should be advised to discontinue aspirin-containing medications and nonsteroidal antiinflammatory agents for at least a week before the biopsy. Direct pressure on the biopsy site and use of a support brassiere are also helpful.

Patient selection for mastectomy and immediate breast reconstruction

Although BCS is excellent treatment for breast cancer in appropriately selected patients, many patients will undergo mastectomy because of personal preference, inability to obtain margin control with a lumpectomy, or because of the inability to receive postlumpectomy breast irradiation. Lumpectomies followed by radiation in women with relatively small breasts or inner-quadrant tumors can result in substantial postlumpectomy deformity and asymmetry, and mastectomy may be preferred in

these patients as well. Consideration of breast reconstruction in these patients before their definitive operations can be an excellent adjunct to their breast cancer management.

Patient-related risk factors

Certain patient-related features, such as smoking, obesity, and major comorbidities can substantially increase the complication rates of breast reconstruction.²³⁻²⁵ These risk factors are detrimental to both immediate and delayed reconstructive outcomes, but they are even more marked contraindications to immediate reconstruction because surgical complications can result in delayed completion of multimodality breast cancer treatment. Other patient-level factors may influence the type of reconstruction offered. For example, women who have had an abdominoplasty or who have had certain abdominal operations are not candidates for transverse rectus myocutaneous flaps because of compromised abdominal wall vascularity.

Cancer-related risk factors and radiation

Radiation severely impairs the wound healing process and permanently damages soft tissues. The immediate damage from radiation is evident within days to weeks and includes tissue edema, inflammation, and desquamation.²⁶ Delayed radiation effects may occur over several months to years, and manifest as fibrosis and atrophy with the replacement of adipose tissue with collagen.^{27,28} Although studies evaluating the impact of radiation on breast reconstruction suggest that autologous reconstructions fare better than implant procedures, the complication rates are considerably high for all types of breast reconstruction.²⁹⁻³¹ Radiation of expander and implant reconstructions is associated with complication rates of up to 50%.³² These complications include capsular contractures, distortion of the reconstructed breast, and chronic chest wall pain and tightness.³³⁻³⁵ Nearly half of radiated implant reconstructions require explantation because of these complications.³⁶

Although autologous tissue reconstructions are relatively more able to withstand radiation-induced tissue damage, these procedures are not immune to fat necrosis, fibrosis, atrophy, and contracture of the flap.^{31,37-39} Early complications such as vessel thrombosis and partial or total flap loss have not been shown to be statistically different between pre- and postradiation flaps, but the incidence of late complications including fat necrosis, flap volume loss, and flap contracture has been shown to be much higher in immediate, compared with delayed, autologous

reconstructions that have received radiation.³⁷ Up to about one-third of patients who receive immediate autologous reconstruction might require a surgical revision later because of severe postradiation deformity. So it is very important to fully communicate these potential adverse outcomes and concerns with each patient during the surgical consultation.

Because of the increased complication risks associated with radiating any type of reconstructed breast, it is worthwhile to initiate strategies in the preoperative period that can identify patients likely to require postmastectomy radiation. Patients can then be better informed about their surgical risks, and these preoperative discussions should include the reconstructive surgeon and the radiation oncologist. Patients with locally advanced breast cancer comprise one obvious category in which immediate breast reconstruction should be approached cautiously (if at all). Patients found to have four or more metastatic axillary lymph nodes will also require postmastectomy radiation,^{40,41} but these patients are not necessarily obvious on presentation, and the extent of disease may not be recognized until the primary operation (including reconstruction) has been completed. An aggressive workup can be helpful in identifying node-positive patients before embarking on definitive breast and reconstructive surgery.

Axillary ultrasonography with ultrasound-guided needle biopsy,⁴²⁻⁴⁵ or sentinel lymph node biopsy, performed as a separate operative procedure (before the mastectomy), are two possible approaches. These options arm the patient and the multidisciplinary team with additional staging information before the definitive operation. Patients identified as node positive can be counseled about the increased risk of needing postmastectomy radiation; in these cases, the multidisciplinary team (including the plastic surgeon) may prefer to discourage the patient from undergoing immediate reconstruction, and the subsequent mastectomy (with or without immediate reconstruction) can be performed in conjunction with standard axillary lymph node dissection.

Kronowitz and colleagues⁴⁶ reported an innovative approach for dealing with immediate reconstruction and radiation risks. The “delayed-immediate” reconstruction strategy involves inserting an inflated tissue expander at the time of skin-sparing mastectomy; the surgical team then makes an expeditious decision about the need for postmastectomy radiation as soon as the final pathology report is available several days later. If no

radiation is necessary, then the patient can either be returned to the operating room for conversion to a transverse rectus myocutaneous flap reconstruction, or she can continue with implant reconstruction. If pathology results indicate a need for postmastectomy radiation, standard delayed reconstruction is performed after completion of all cancer treatment. Early results with this approach are promising, but the potential risk of radiation-related tissue expander complications could result in interruptions of the postmastectomy radiotherapy, compromising the cancer care.

Intraoperative considerations

Planning the surgical biopsy or lumpectomy incision

Common principles of wound healing are used to determine orientation of skin incisions for breast biopsies and cancer-directed lumpectomies. But diverse opinions exist about achieving optimal cosmetic results. Lesions located in proximity to the nipple-areolar complex are well suited for periareolar incisions, and these scars are nicely camouflaged by the normal contrast in skin pigmentation at this border. One should be careful to place the incision right on the circumareolar margin, because a scar within the areola may become hypopigmented and hypertrophic if placed on the areolar skin.⁴⁷

Selection of the optimal incision for more peripherally located breast tumors warrants consideration of other factors. Although it may be reasonable to rely on tunneling along a long tract of normal breast tissue to excise a benign fibroadenoma through a periareolar incision, the safety of this approach with a cancerous lesion is less clear, because of the uncertain risks related to exposing otherwise unaffected breast tissue to the malignant tissue. For patients requiring additional surgery for margin control, this approach will increase the complexity of a reexcision lumpectomy. So skin incisions that overlay the breast tumor more directly are preferred. It can also be useful to plan the incision site with consideration of possible future mastectomy needs. The breast biopsy or lumpectomy incision should be situated in a site that can be readily encompassed within subsequent mastectomy incisions, in the event that margin control does not permit BCS.

Surgeons frequently refer to the “Langer’s lines,”⁴⁸ or “relaxed skin tension lines,”⁴⁹ when designing the direction and orientation of breast incisions because the final scar is expected to have the least amount of contraction

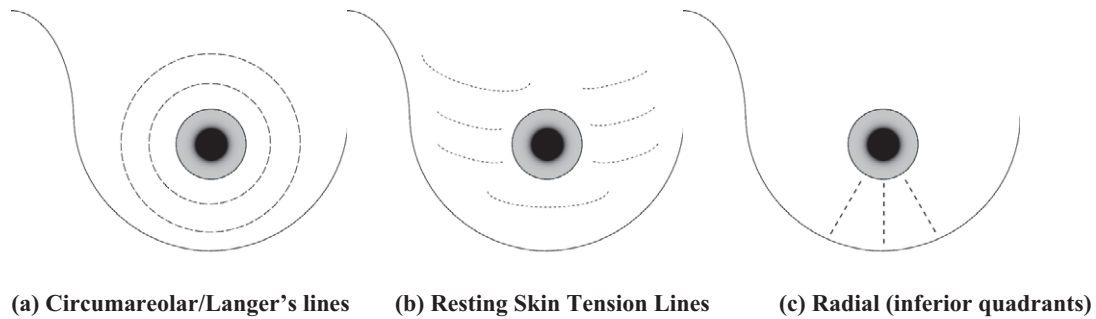


Figure 1. Suggested orientation lines for breast biopsies and lumpectomies.

when it is parallel to these lines. Because these relaxed tension lines are generally the same as wrinkle lines, a scar designed parallel to them will be the least conspicuous. Although the Viennese pathologist Langer described the shifting appearance of these lines with different patient positions, they are frequently thought to be configured as concentric circles radiating from the central nipple-areolar complex, and this model forms the basis for many breast incisions. The resting skin tension lines are sometimes parallel to these concentric circumareolar lines, but in the upper outer quadrants and in a large, pendulous breast, the optimal skin incision orientation may not be completely obvious. Many surgeons have minimized nipple retraction after resection of lower hemisphere tumors by using vertical or radially oriented incisions, as promoted by the National Surgical Adjuvant Breast Project (NSABP).⁵⁰ Figure 1 demonstrates the various orientations for breast incisions that have been presented by different surgical groups. The final site selected by the surgeon should be based on the appearance of the individual patient skin lines, the potential for incorporation into a mastectomy resection, and the final position of the scar in relationship to clothing, such as bathing suits and brassieres. For superficially located tumors, an ellipse of overlying skin should be resected en bloc with the lumpectomy. This improves likelihood of a negative anterior margin. Also, leaving behind a thin skin flap will increase the risk of skin necrosis during subsequent breast irradiation.

Planning the lumpectomy resection

The breast will generally retain the most natural contour if the lumpectomy cavity walls are not reapproximated; the seroma cavity should be allowed to accumulate in this open space. Placement of clips at the perimeter and base of the lumpectomy cavity is a useful maneuver that will facilitate planning of subsequent breast radiation fields and, in particular, a final boost dose if required.

Also, because the lumpectomy cavity consolidates, these clips will serve as useful markers for diagnostic mammography views for longterm breast cancer surveillance.

A variety of mastopexy procedures have been proposed that involve reapproximation of the space left behind by a large lumpectomy, sometimes in conjunction with concomitant contralateral breast surgery to optimize symmetry.^{51,52} This approach may require the expertise of a plastic or reconstruction surgeon (and substantial preoperative planning), and the subsequent radiation treatment to the cancerous breast may alter the symmetry needs. Very importantly, it should also be noted that extensive internal remodeling and shifting of tissue planes within the breast can increase the complexity of a subsequent reexcision lumpectomy in the event that margin control is not achieved. One relatively straightforward oncoplastic surgical approach to a large lumpectomy cavity involves undermining the entire mammary gland at the level of the pectoralis fascia, and then essentially sliding the remaining breast volume over so that it fills in some of the lumpectomy defect. This maneuver can be especially useful for large lumpectomy specimens within the inferior breast hemisphere.

Maneuvers to minimize hematoma risk continue during the perioperative phase. Careful intraoperative attention to hemostasis is essential. Patients should wear a comfortable support brassiere day and night for 1 to 2 weeks postoperatively. This can be particularly important for patients with large, pendulous breasts because dependency of the breast in the early postoperative period can result in shearing and avulsion of friable vessels at the lumpectomy cavity walls.

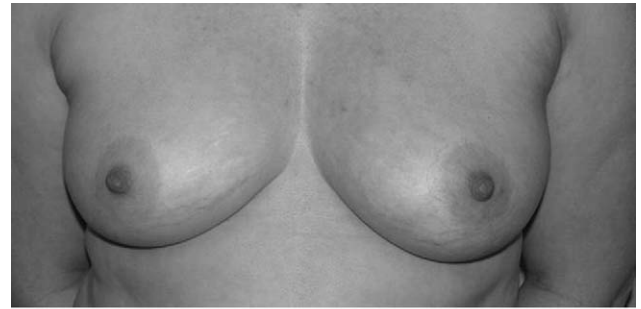Planning the mastectomy incision

Conventional mastectomy without immediate breast reconstruction. The majority of breast cancer patients undergoing mastectomy will have transversely oriented

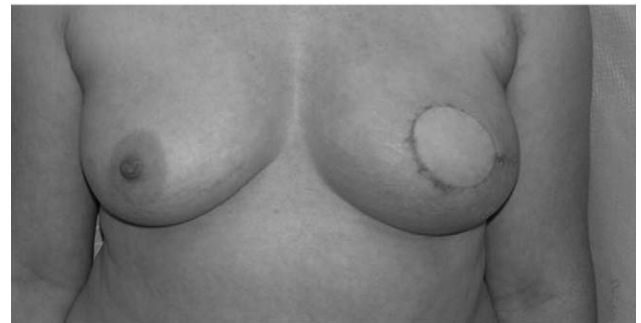incisions over the chest wall, created by elliptical incisions made superior and inferior to the nipple-areolar complex. When feasible, it is useful to base the resulting scar low in the chest wall, with a relatively longer superior skin flap. This leaves a less prominent scar, and a long chest wall flap that can facilitate delayed reconstruction.

It is always beneficial to avoid the axillary-based cutaneous deformities commonly called “dog-ears.” These flaps of redundant skin and fat can cause considerable patient discomfort because of their bulky underarm sensations. Extending the elliptical skin incisions even more laterally will sometimes minimize this problem. Unfortunately, obese patients may have a bulky fat pad that extends completely around the back and without the breast to pull the axillary portion of this tissue forward, it is left to droop from the underarm. Some surgical maneuvers that have been suggested as ways to minimize this axillary deformity have involved incorporation of a “fish-shaped” triangulation of the incision at its lateral aspect.⁵³ Suction-assisted lipectomy is another alternative to improve the contour of the axillary region, but this often must be used in conjunction with direct excision of the excess skin and adipose tissue.

Skin-sparing mastectomy with immediate breast reconstruction. Skin-sparing mastectomy has become a popular adjunct to immediate breast reconstruction. It has been shown to be oncologically safe, with local recurrence rates equivalent to those observed after conventional mastectomy.^{54,55} This technique involves the use of a circumareolar mastectomy incision, with creation of very long skin flaps extending to the usual mastectomy boundaries (clavicle superiorly, lateral border of the sternum medially, inframammary fold inferiorly, and latissimus dorsi muscle laterally). The central nipple-areolar complex is resected with the breast tissue, but any uninvolved breast skin and the inframammary fold are preserved. Tumor biopsy scars are resected en bloc with the circumareolar incision if they are centrally located, but a peripheral tumor biopsy scar is resected separately from the circumareolar incision. It is not necessary, as demonstrated in several studies, to separately resect skin puncture sites left by percutaneous needle biopsies because the incidence of biologically significant tumor seeding at these sites is quite low.⁵⁶⁻⁵⁹ A lateral extension to this incision can be made to facilitate any necessary axillary surgery. Patients receiving transverse rectus myocutaneous flap reconstruction will have abdominal skin available to fill in the central defect of the resected nipple-



A



B

Figure 2. A 46-year-old woman with invasive ductal carcinoma in situ, treated with skin-sparing mastectomy and transverse rectus abdominis myocutaneous flap reconstruction. (A) Preoperative and (B) postoperative photographs.

areolar complex; most plastic surgeons delay the reconstruction of the nipple-areolar complex and use a combination of local flaps and skin grafts to recreate the areola and papule. For most patients, a skin-sparing mastectomy offers an aesthetic enhancement for autologous reconstructions, with improved shaping of the breast mound⁶⁰ (Fig. 2). For patients receiving subpectoral tissue expander or implant reconstructions, incisions are made in an elliptical fashion and closed with a transverse orientation over the pectoralis muscle. In cases of severe breast ptosis, the mastectomy flaps can be designed as a breast reduction (Fig. 3). In these patients, this type of skin resection is aesthetically preferred over a skin-sparing mastectomy because of the correction of the ptotic skin envelope while minimizing breast scars. It is especially important in these patients to perform an atraumatic mastectomy resection because the skin flaps tend to be longer and more susceptible to ischemia.

The inframammary fold is a crucial element defining the shape and structure of the female breast. It is undetectable before puberty, but postpuberty, the inframammary fold defines the inferior extent of the breast. It is

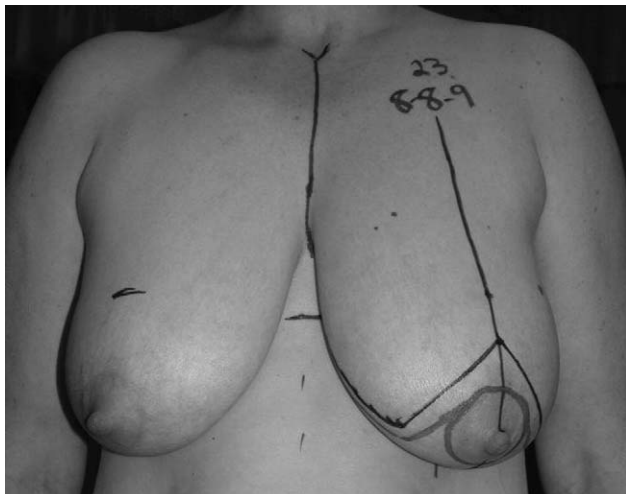


Figure 3. A 52-year-old woman with multifocal ductal carcinoma in situ, treated with simple mastectomy designed as a breast reduction.

usually located at the inferior margin of the pectoralis major at the sixth and sometimes the seventh rib. The anatomy of the inframammary fold has been studied extensively, but the exact composition has been elusive. Recent studies support the hypothesis of zone of adherence or fusion of superficial fascial layers over the chest wall, rather than a classic hypothesis of a distinct ligamentous structure connecting all layers to the chest wall.⁶¹ It is difficult to recreate the inframammary fold and achieve the natural contour of the breast once it is destroyed. One way to securely mark the inframammary fold is to draw the fold preoperatively and then place a series of skin staples along the fold intraoperatively. Preservation of this structure during mastectomy or immediate reconstruction is very important and will facilitate both autogenous and prosthetic reconstruction, yielding better aesthetic outcomes.⁶²⁻⁶⁵

Another notable structure that requires careful handling during mastectomy is the rectus abdominis fascia just inferior to the pectoralis muscles. This part of the rectus fascia connects the lower edge of the pectoralis major to the rectus abdominis, and is quite important in creating submuscular pockets for the implants. Submuscular placement of tissue expanders is advantageous because an additional layer of well-vascularized, healthy tissue is interposed between the implant and the skin. It softens the contours of the reconstructed breast and decreases the incidence of complications such as implant exposure or extrusion and infection. When a submuscular implant pocket is dissected, the lower third of the pocket is often covered by the fascial connection be-

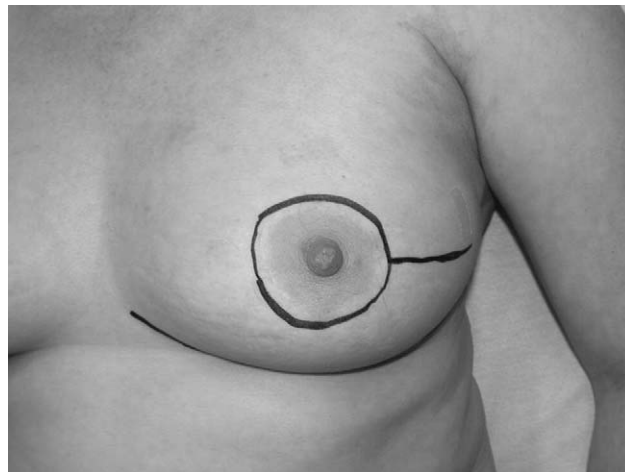


Figure 4. Lateral extension of the skin-sparing mastectomy for improved access.

tween the pectoralis major and rectus abdominis muscles. When a superficial wound problem occurs, this fascial layer can provide important soft tissue coverage over the implant. So preservation of this fascia along with the pectoralis major muscle is crucial to successful expander and implant reconstruction.⁶⁶

A technical point that aids in a successful reconstruction involves the medial extent of the mastectomy resection. Overzealous dissection and crossing of the midline of the chest can lead to a midline confluence called symmastia, which is a very difficult complication to correct.⁵⁸ In women who smoke, it is helpful to preserve the internal mammary perforators along the midline, which can augment perfusion to the mastectomy flaps and potentially decrease the risk of tissue necrosis.

Mastectomy skin flaps are also critically important in both implant and autologous breast reconstruction, and the strict use of atraumatic techniques during skin flap dissection and retraction cannot be overemphasized with the skin-sparing approach. Maintaining adequate exposure through a limited incision can necessitate increased traction on the mastectomy skin flaps, and this can result in an increased incidence of skin flap loss.^{67,68} Areas of full thickness skin loss over an implant may ultimately lead to implant removal, delay of reconstruction, and delays in delivering adjuvant therapy. When skin flaps are noted to be severely traumatized after mastectomy, immediate implant reconstruction may need to be aborted or, in the setting of autologous reconstruction, the flap inset delayed. If a better access is required in skin-sparing mastectomy, a lateral transverse

incision can be made to extend the surgical field to avoid traumatizing the skin flaps (Fig. 4).

Planning the axillary incision

For patients undergoing axillary surgery in conjunction with lumpectomy, it is generally preferable to use two separate incisions. The drainage catheter that will be used to decompress an axillary seroma can compromise the cosmetic result by decompressing the breast seroma. A long single incision covering both the axilla (for sentinel node biopsy or a standard axillary dissection) and the breast creates a large scar that continues to contract and become fibrotic after adjuvant radiation therapy.

An additional technical consideration with axillary surgery is related to the thoracodorsal arteriovenous bundle. These vessels are most commonly used in microsurgical reconstructions or latissimus dorsi breast reconstructions. Not only can direct injuries to these vessels occur during these procedures, but indirect insults such as those from scarring and fibrosis can render the thoracodorsal vessels no longer suitable for microsurgical anastomosis. Internal mammary vessels can be used as a second option for microsurgical reconstruction, but they are known to have less predictable anatomy and more variations. So atraumatic techniques in axillary surgery to preserve the integrity of the thoracodorsal bundle will greatly aid future reconstruction.

Postoperative considerations

Maneuvers to avoid breast hematoma after lumpectomy, as noted previously, continue during the postoperative period, with use of support brassieres and even pressure dressings for selected patients. In the chronic, long-term postoperative period, there are several situations in which patients might benefit from referral to the plastic reconstructive team. Mastectomy patients desiring delayed reconstruction are one obvious example, but the plastic surgeons can also reverse other deformities left by the initial breast cancer operation and adjuvant radiation therapy.

Reconstruction of lumpectomy defects

The final appearance of the cancerous breast treated with breast-sparing intent cannot be appreciated until at least 6 months after completion of breast radiation, when the effects of fibrosis and lumpectomy cavity consolidation have fully matured. The resulting volume reduction, asymmetry, and retraction of the nipple-areolar complex, lumpectomy scar, or both, may leave the pa-

tient with an unsatisfactory cosmetic result that can be difficult to correct with external prostheses.

Fortunately, plastic surgery can intervene in many of these patients by offering implant augmentation, contralateral reduction, or autogenous tissue volume replacement (often with the latissimus dorsi flap) to restore symmetry. Of course, these patients should undergo a complete breast reevaluation before their plastic surgery to rule out the presence of a coexisting local recurrence or interval development of a new breast primary cancer.

For patients undergoing BCS, assessment should be made of their potential aesthetic outcomes, especially when a large lumpectomy resection is required, and women should be informed of their postlumpectomy reconstructive options. For those with large breasts, a reduction may be required on the opposite side for symmetry. Women with smaller breasts may lose substantial volume, necessitating an augmentation procedure, such as that with an implant. Another option for reconstructing large lumpectomy defects is an early delayed latissimus dorsi muscle flap. This is performed approximately 1 week after lumpectomy, when the final pathology results are available. The muscle can be harvested endoscopically, avoiding any surgical scars on the back, and rotated into the lumpectomy defect to replace the missing volume. When a large lumpectomy is expected to yield substantial asymmetry, as noted previously, the patient should be encouraged to give serious consideration to mastectomy and immediate reconstruction. Many plastic surgeons will be more confident of achieving an aesthetically acceptable result with this approach, as opposed to reconstruction of a lumpectomy defect within a radiation field. We recognize that some patients will prioritize the preservation of any breast volume or the nipple-areolar complex (regardless of breast deformity and at the expense of maintaining symmetry), and in these situations, the surgical team must focus on counseling the patient about realistic expectations for cosmetic outcomes.

Suction lipectomy for mastectomy “dog-ears” and other defects

Suction lipectomy (better known as liposuction) is a useful adjunct to breast reconstruction because it can correct undesirable contour irregularities or improve the fit of the breast prostheses.^{69,70} Liposuction requires only small incisions for cannula insertion and results in minimal scars. For breast procedures, the cannula sites are

strategically placed within less conspicuous areas such as the inframammary fold, the periareolar area, or the axillary skin fold, providing easy access to the entire breast tissue while leaving scars that are effectively camouflaged.^{71,72} Liposuction allows for both volume reduction and recontouring of difficult areas such as the inframammary fold and lateral breast borders, which is especially useful with mastectomy procedures in heavier patients who tend to have excess fatty tissue in the axillary regions.^{66,73} So it is very effective as a minimally invasive option to correct asymmetry or undesirable contour irregularities after either a mastectomy or reconstructive procedure.

In conclusion, within the past few decades, both breast cancer treatment and reconstructive options have undergone numerous changes and innovations. Because as breast reconstruction has become accessible to more women, better communication and cooperation between oncologic and reconstructive surgeons is essential to achieve the most optimal aesthetic outcomes. This communication should begin during treatment planning phases and should continue through the post-treatment followup and surveillance phases.

REFERENCES

- Boring CC, Squires TS, Tong T, Montgomery S. Cancer statistics, 1994. *CA Cancer J Clin* 1994;44:7–26.
- Ries L, Eisner M, Kosary M. SEER Cancer Statistics Review, 1973–1999. Bethesda, MD: National Cancer Institute; 2002.
- Stewart SL, King JB, Thompson TD, et al. Cancer mortality surveillance—United States, 1990–2000. *MMWR Surveill Summ* 2004;53:1–108.
- Newman LA, Kuerer HM. Advances in breast conservation therapy. *J Clin Oncol* 2005;23:1685–1697.
- Fisher B, Anderson S, Bryant J, et al. Twenty-year follow-up of a randomized trial comparing total mastectomy, lumpectomy, and lumpectomy plus irradiation for the treatment of invasive breast cancer. *N Engl J Med* 2002;347:1233–1241.
- Veronesi U, Cascinelli N, Mariani L, et al. Twenty-year follow-up of a randomized study comparing breast-conserving surgery with radical mastectomy for early breast cancer. *N Engl J Med* 2002;347:1227–1232.
- Morris AD, Morris RD, Wilson JF, et al. Breast-conserving therapy vs mastectomy in early-stage breast cancer: a meta-analysis of 10-year survival. *Cancer J Sci Am* 1997;3:6–12.
- NIH consensus conference. Treatment of early-stage breast cancer. *JAMA* 1991;265:391–395.
- Alderman AK, Wilkins EG, Lowery JC, et al. Determinants of patient satisfaction in postmastectomy breast reconstruction. *Plast Reconstr Surg* 2000;106:769–776.
- Locker GY, Sainsbury JR, Cuzick J. Breast surgery in the 'Arimidex, Tamoxifen Alone or in Combination' (ATAC) trial: American women are more likely than women from the United Kingdom to undergo mastectomy. *Cancer* 2004;101:735–740.
- Morrow M, Scott SK, Menck HR, et al. Factors influencing the use of breast reconstruction postmastectomy: a National Cancer Database study. *J Am Coll Surg* 2001;192:1–8.
- Morrow M, White J, Moughan J, et al. Factors predicting the use of breast-conserving therapy in stage I and II breast carcinoma. *J Clin Oncol* 2001;19:2254–2262.
- Tseng JF, Kronowitz SJ, Sun CC, et al. The effect of ethnicity on immediate reconstruction rates after mastectomy for breast cancer. *Cancer* 2004;101:1514–1523.
- Cox CE, Reintgen DS, Nicosia SV, et al. Analysis of residual cancer after diagnostic breast biopsy: an argument for fine-needle aspiration cytology. *Ann Surg Oncol* 1995;2:201–206.
- Lieberman L, Goodstine SL, Dershaw DD, et al. One operation after percutaneous diagnosis of nonpalpable breast cancer: frequency and associated factors. *AJR Am J Roentgenol* 2002;178:673–679.
- Tartter PI, Bleiweiss IJ, Levchenko S. Factors associated with clear biopsy margins and clear reexcision margins in breast cancer specimens from candidates for breast conservation. *J Am Coll Surg* 1997;185:268–273.
- Luu HH, Otis CN, Reed WP Jr, et al. The unsatisfactory margin in breast cancer surgery. *Am J Surg* 1999;178:362–366.
- Yim JH, Barton P, Weber B, et al. Mammographically detected breast cancer. Benefits of stereotactic core versus wire localization biopsy. *Ann Surg* 1996;223:688–697; discussion 697–700.
- Meyer JE, Smith DN, Lester SC, et al. Large-core needle biopsy of nonpalpable breast lesions. *JAMA* 1999;281:1638–1641.
- Lieberman L, LaTrenta LR, Dershaw DD, et al. Impact of core biopsy on the surgical management of impalpable breast cancer. *AJR Am J Roentgenol* 1997;168:495–499.
- Edge S, Ottesen R, Lepisto E, et al. Surgical biopsy to diagnose breast cancer adversely affects outcomes of breast cancer care: finding from the National Comprehensive Cancer Network. 2005 San Antonio Breast Cancer Symposium Abstract No. 12. San Antonio, TX; 2005.
- Fisher B, Brown A, Mamounas E, et al. Effect of preoperative chemotherapy on local-regional disease in women with operable breast cancer: findings from National Surgical Adjuvant Breast and Bowel Project B-18. *J Clin Oncol* 1997;15:2483–2493.
- Alderman AK, Wilkins EG, Kim HM, Lowery JC. Complications in postmastectomy breast reconstruction: two-year results of the Michigan Breast Reconstruction Outcome Study. *Plast Reconstr Surg* 2002;109:2265–2274.
- Hartrampf CR Jr, Bennett GK. Autogenous tissue reconstruction in the mastectomy patient. A critical review of 300 patients. *Ann Surg* 1987;205:508–519.
- Schefflan M, Dinner MI. The transverse abdominal island flap: part I. Indications, contraindications, results, and complications. *Ann Plast Surg* 1983;10:24–35.
- Mansfield C. Effects of radiation therapy on wound healing after mastectomy. *Clin Plast Surg* 1979;6:19–26.
- Fajardo LF. Morphology of radiation effects on normal tissues. In: Perez C, Brady L, eds. Principles and practices of radiation oncology. 2nd ed. New York City: Lippincott; 1992:114–123.
- Fajardo LF. Basic mechanisms and general morphology of radiation injury. *Semin Roentgenol* 1993;28:297–302.
- Kuske RR, Schuster R, Klein E, et al. Radiotherapy and breast

- reconstruction: clinical results and dosimetry. *Int J Radiat Oncol Biol Phys* 1991;21:339–346.
30. Hunt KK, Baldwin BJ, Strom EA, et al. Feasibility of postmastectomy radiation therapy after TRAM flap breast reconstruction. *Ann Surg Oncol* 1997;4:377–384.
 31. Williams JK, Carlson GW, Bostwick J 3rd, et al. The effects of radiation treatment after TRAM flap breast reconstruction. *Plast Reconstr Surg* 1997;100:1153–1160.
 32. Spear SL, Onyewu C. Staged breast reconstruction with saline-filled implants in the irradiated breast: recent trends and therapeutic implications. *Plast Reconstr Surg* 2000;105:930–942.
 33. Evans GR, Schusterman MA, Kroll SS, et al. Reconstruction and the radiated breast: is there a role for implants? *Plast Reconstr Surg* 1995;96:1111–1115; discussion 1116–1118.
 34. Kraemer O, Andersen M, Siim E. Breast reconstruction and tissue expansion in irradiated versus not irradiated women after mastectomy. *Scand J Plast Reconstr Surg Hand Surg* 1996;30:201–206.
 35. Robb G. Reconstructive surgery. In: Hunt K, Robb G, Strom E, Ueno NT, eds. *Breast cancer*. New York: Springer-Verlag; 2001: 255–285.
 36. Newman LA, Kuerer HM, Hunt KK, et al. Feasibility of immediate breast reconstruction for locally advanced breast cancer. *Ann Surg Oncol* 1999;6:671–675.
 37. Tran NV, Evans GR, Kroll SS, et al. Postoperative adjuvant irradiation: effects on tranverse rectus abdominis muscle flap breast reconstruction. *Plast Reconstr Surg* 2000;106:313–317; discussion 318–320.
 38. Tran NV, Chang DW, Gupta A, et al. Comparison of immediate and delayed free TRAM flap breast reconstruction in patients receiving postmastectomy radiation therapy. *Plast Reconstr Surg* 2001;108:78–82.
 39. Rogers NE, Allen RJ. Radiation effects on breast reconstruction with the deep inferior epigastric perforator flap. *Plast Reconstr Surg* 2002;109:1919–1924; discussion 1925–1926.
 40. Recht A, Edge SB. Evidence-based indications for postmastectomy irradiation. *Surg Clin North Am* 2003;83:995–1013.
 41. Recht A, Edge SB, Solin LJ, et al. Postmastectomy radiotherapy: clinical practice guidelines of the American Society of Clinical Oncology. *J Clin Oncol* 2001;19:1539–1569.
 42. Brancato B, Zappa M, Bricolo D, et al. Role of ultrasound-guided fine needle cytology of axillary lymph nodes in breast carcinoma staging. *Radiol Med (Torino)* 2004;108:345–355.
 43. Nori J, Bazzocchi M, Boeri C, et al. Role of axillary lymph node ultrasound and large core biopsy in the preoperative assessment of patients selected for sentinel node biopsy. *Radiol Med (Torino)* 2005;109:330–344.
 44. Damera A, Evans AJ, Cornford EJ, et al. Diagnosis of axillary nodal metastases by ultrasound-guided core biopsy in primary operable breast cancer. *Br J Cancer* 2003;89:1310–1313.
 45. Krishnamurthy S, Sneige N, Bedi DG, et al. Role of ultrasound-guided fine-needle aspiration of indeterminate and suspicious axillary lymph nodes in the initial staging of breast carcinoma. *Cancer* 2002;95:982–988.
 46. Kronowitz SJ, Hunt KK, Kuerer HM, et al. Delayed-immediate breast reconstruction. *Plast Reconstr Surg* 2004;113:1617–1628.
 47. McKinney P. Gynecomastia. In: Aston S, Beasley R, Thorne C, eds. *Grabb and Smith's plastic surgery*. 5th ed. Philadelphia: Lippincott-Raven Publishers; 1997.
 48. Wilhelmi BJ, Blackwell SJ, Phillips LG. Langer's lines: to use or not to use. *Plast Reconstr Surg* 1999;104:208–214.
 49. Borges AF. Relaxed skin tension lines. *Dermatol Clin* 1989;7:169–177.
 50. Margolese R, Poisson R, Shibata H, et al. The technique of segmental mastectomy (lumpectomy) and axillary dissection: A syllabus from the National Surgical Adjuvant Breast Project workshops. *Surgery* 1987;102:828–834.
 51. Anderson BO, Masetti R, Silverstein MJ. Oncoplastic approaches to partial mastectomy: an overview of volume-displacement techniques. *Lancet Oncol* 2005;6:145–157.
 52. Clough KB, Lewis JS, Couturaud B, et al. Oncoplastic techniques allow extensive resections for breast-conserving therapy of breast carcinomas. *Ann Surg* 2003;237:26–34.
 53. Nowacki MP, Towpik E. A fish shaped incision for mastectomy. *Surg Gynecol Obstet* 1988;167:251–252.
 54. Newman LA, Kuerer HM, Hunt KK, et al. Presentation, treatment, and outcome of local recurrence after skin-sparing mastectomy and immediate breast reconstruction. *Ann Surg Oncol* 1998;5:620–626.
 55. Rivadeneira DE, Simmons RM, Fish SK, et al. Skin-sparing mastectomy with immediate breast reconstruction: a critical analysis of local recurrence. *Cancer J* 2000;6:331–335.
 56. Knight R, Horiuchi K, Parker SH, et al. Risk of needle-track seeding after diagnostic image-guided core needle biopsy in breast cancer. *JSL* 2002;6:207–209.
 57. Kopans DB, Gallagher WJ, Swann CA, et al. Does preoperative needle localization lead to an increase in local breast cancer recurrence? *Radiology* 1988;167:667–668.
 58. Chen AM, Haffty BG, Lee CH. Local recurrence of breast cancer after breast conservation therapy in patients examined by means of stereotactic core-needle biopsy. *Radiology* 2002;225:707–712.
 59. King TA, Hayes DH, Cederbom GJ, et al. Biopsy technique has no impact on local recurrence after breast-conserving therapy. *Breast J* 2001;7:19–24.
 60. Hidalgo DA. Aesthetic refinement in breast reconstruction: complete skin-sparing mastectomy with autogenous tissue transfer. *Plast Reconstr Surg* 1998;102:63–70; discussion 71–72.
 61. Muntan CD, Sundine MJ, Rink RD, Acland RD. Inframammary fold: a histologic reappraisal. *Plast Reconstr Surg* 2000;105:549–556; discussion 557.
 62. Carlson GW. Skin sparing mastectomy: anatomic and technical considerations. *Am Surg* 1996;62:151–155.
 63. Carlson GW, Grossl N, Lewis MM, et al. Preservation of the inframammary fold: what are we leaving behind? *Plast Reconstr Surg* 1996;98:447–450.
 64. Rand RP, Byrd DR, Anderson BO, Moe R. Skin-sparing mastectomy with immediate tissue reconstruction. *West J Med* 1996;164:166.
 65. Singletary SE, Kroll SS. Skin-sparing mastectomy with immediate breast reconstruction. *Adv Surg* 1996;30:39–52.
 66. Maxwell G, Hammond D. Breast reconstruction following mastectomy and surgical management of the patient with high-risk breast disease. In: Aston S, Beasley R, Thorne C, eds. *Grabb and Smith's plastic surgery*. 5th ed. Philadelphia: Lippincott-Raven Publishers; 1997:763–784.
 67. Gendy RK, Able JA, Rainsbury RM. Impact of skin-sparing mastectomy with immediate reconstruction and breast-sparing

- reconstruction with miniflaps on the outcomes of oncoplastic breast surgery. *Br J Surg* 2003;90:433–439.
68. Hultman CS, Daiza S. Skin-sparing mastectomy flap complications after breast reconstruction: review of incidence, management, and outcome. *Ann Plast Surg* 2003;50:249–255; discussion 255.
 69. Drever JM. Suction lipectomy: an excellent adjunct to improve the results of breast reconstruction with RAM flaps. *Aesthetic Plast Surg* 1990;14:275–279.
 70. Drever JM. Lipocontouring in breast reconstructive surgery. *Aesthetic Plast Surg* 1996;20:285–289.
 71. Goes JC, Landecker A. Ultrasound-assisted lipoplasty (UAL) in breast surgery. *Aesthetic Plast Surg* 2002;26:1–9.
 72. Toledo LS, Matsudo PK. Mammoplasty using liposuction and the periareolar incision. *Aesthetic Plast Surg* 1989;13:9–13.
 73. Matarasso A, Courtiss EH. Suction mammoplasty: the use of suction lipectomy to reduce large breasts. *Plast Reconstr Surg* 1991;87:709–717.